

Ultrasonography of the Adult Thoracic and Lumbar Spine for Central Neuraxial Blockade

Ki Jinn Chin, F.R.C.P.C.,* Manoj Kumar Karmakar, M.D.,† Philip Peng, F.R.C.P.C.‡

ABSTRACT

The role of ultrasound in central neuraxial blockade has been underappreciated, partly because of the relative efficacy of the landmark-guided technique and partly because of the perceived difficulty in imaging through the narrow acoustic windows produced by the bony framework of the spine. However, this also is the basis for the utility of ultrasound: an interlaminar window that permits passage of sound waves into the vertebral canal also will permit passage of a needle. In addition, ultrasound aids in identification of intervertebral levels, estimation of the depth to epidural and intrathecal spaces, and location of important landmarks, including the midline and interlaminar spaces. This can facilitate neuraxial blockade, particularly in patients with difficult surface anatomic landmarks. In this review article, the authors summarize the current literature, describe the key ultrasonographic views, and propose a systematic approach to ultrasound imaging for the performance of spinal and epidural anesthesia in the adult patient.

ULTRASOUND guidance has revolutionized regional anesthesia, particularly peripheral nerve blockade. Its application in neuraxial blockade has not yet enjoyed the

same popularity, even though spinal and epidural anesthesia are the most widely used regional anesthetic techniques. This can be attributed both to the efficacy of the traditional landmark-guided technique of neuraxial blockade and to the limitations of ultrasonography of the adult spine. Ultrasonographic visualization of structures encased within the bony vertebrae in adults is possible only through the interlaminar spaces between adjacent vertebrae. However, this is also the basis for the utility of ultrasound in neuraxial blockade: if an interlaminar window that permits passage of sound waves into the vertebral canal can be identified, the same window will permit passage of a needle into the epidural or intrathecal space.

The purpose of this article is 2-fold: first, to describe the relevant anatomy and sonoanatomy of the adult lumbar and thoracic spine; and second, to propose a systematic approach to ultrasound imaging of the spine in the performance of spinal and epidural anesthesia. We also briefly review the current state of knowledge on the use of ultrasound for neuraxial blockade.

History of Interventional Ultrasonography of the Adult Spine

The first report of ultrasound-guided lumbar puncture appeared in the Russian literature in 1971.¹ Nine years later, Cork *et al.* described the use of ultrasound to delineate neuraxial anatomy.² Although the images were of poor quality by today's standards, they were able to define the lamina, ligamentum flavum, spinal canal, and the vertebral body. Thereafter, ultrasound was used mostly to preview the spinal anatomy and measure the distances to the lamina and epidural space before epidural puncture.^{3,4} Between 2001 and 2004, Grau and colleagues conducted a series of investigations that demonstrated the utility of ultrasound in epidural analgesia and were pivotal in improving our understanding of spinal sonography.⁵⁻¹⁵ Despite this, only three case reports appeared in the adult anesthetic literature between the end of 2004 and beginning of 2007,¹⁶⁻¹⁸ and it is likely that the quality and availability of ultrasound imaging at the time hindered research in this area. Since then, there have been an increasing number of anesthesia-related publications (in-

* Assistant Professor, ‡ Associate Professor, Department of Anesthesia, Toronto Western Hospital, University of Toronto, Toronto, Ontario, Canada. † Associate Professor, Department of Anaesthesia and Intensive Care, The Chinese University of Hong Kong, Prince of Wales Hospital, Shatin, New Territories, Hong Kong.

Received from the Department of Anesthesia, Toronto Western Hospital, University of Toronto, Toronto, Ontario, Canada. Submitted for publication September 3, 2010. Accepted for publication January 7, 2011. Support was provided solely from institutional and/or departmental sources. None of the authors have any financial interest in the subject matter, materials, or equipment discussed or in competing materials.

Address correspondence to Dr. Peng: Department of Anesthesia, Toronto Western Hospital, 399 Bathurst Street, Toronto, Ontario, M5T 2S8, Canada. philip.peng@uhn.on.ca. This article may be accessed for personal use at no charge through the Journal Web site, at www.anesthesiology.org.

Copyright © 2011, the American Society of Anesthesiologists, Inc. Lippincott Williams & Wilkins. Anesthesiology 2011; 114:1459-85

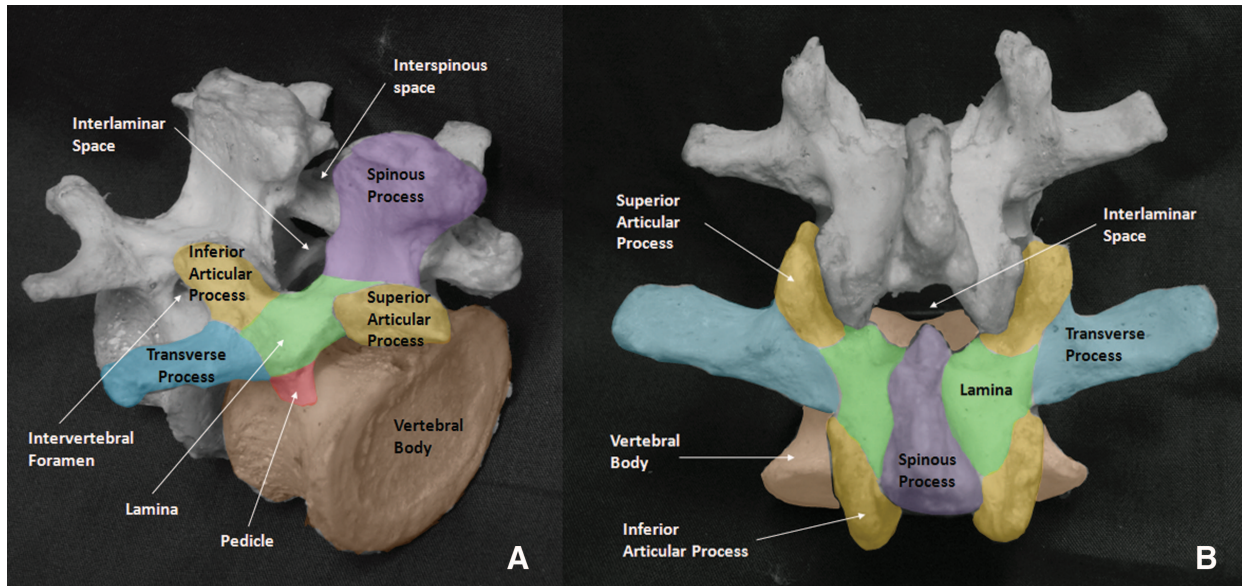


Fig. 1. Three-quarter oblique view (A) and posterior view (B) of adjacent lumbar vertebrae. The interlaminar space is located posteriorly and is bounded by the bases of the spinous processes, the laminae, and the inferior articular processes. It is roofed over by the ligamentum flavum. The interspinous space lies in the midline and is filled by the supraspinous and interspinous ligaments. The intervertebral foramina are located laterally and are bounded by the pedicles, the vertebral body, the laminae, and the superior and inferior articular processes and contain the spinal nerve roots and their accompanying blood vessels. (Image used with permission from www.usra.ca.)

cluding a set of National Institute for Health and Clinical Excellence [NICE]) guidelines¹⁹) on ultrasound-guided epidural and spinal anesthesia. There also has been interest in the use of the technique by emergency physicians to guide lumbar puncture.^{20–23}

General Anatomy of the Spine

A typical vertebra has two components: the body and the arch. The vertebral arch is composed of the following elements: pedicles, lamina, transverse processes, spinous process, and superior and inferior articular processes (fig. 1). Adjacent vertebrae articulate at the facet joints between superior and inferior articular processes and at the intervertebral discs between vertebral bodies. In this article, we use the terms “interlaminar space” and “interspinous space” to refer to the gaps between adjacent laminae and spinous processes, respectively.

The vertebral canal is formed by the spinous process and lamina posteriorly, the pedicles laterally, and the vertebral body anteriorly. The posterior longitudinal ligament runs along the length of the anterior wall of the vertebral canal. The only openings into the vertebral canal are the intervertebral foramina along its lateral wall, from whence the spinal nerve roots emerge, and the interlaminar spaces on its posterior wall. The ligamentum flavum is a dense connective tissue ligament that bridges the interlaminar spaces. It is arch-like in cross-section and is thickest in the midline. The ligamentum flavum attaches to the anterior surface of the lamina above but splits to attach to

both the posterior surface (superficial component) and anterior surface (deep component) of the lamina below.²⁴ The spinous processes are connected at their tips by the supraspinous ligament, which is a strong fibrous cord, and along their length by the interspinous ligament, which is thin and membranous.

Within the vertebral canal lie the thecal sac (formed by the dura mater and arachnoid mater) and its contents (spinal cord, cauda equina, and cerebrospinal fluid). The epidural space is the space within the vertebral canal but outside the thecal sac. The anatomy of the epidural space is more complex than is portrayed in most anatomy textbooks.²⁵ It is divided into anterior, lateral, and posterior epidural spaces with respect to the thecal sac, with the posterior epidural space being of most interest in neuraxial blockade. The posterior epidural space is not continuous. Instead, it is segmented into a series of fat-filled compartments in the interlaminar areas. The lateral epidural spaces are located at the level of each intervertebral foramen and contain spinal nerves, radicular vessels, and fat. The primary structure of importance in the anterior epidural space is the internal vertebral venous plexus.

The Lumbar Spine

Gross Anatomy

The posterior surface of the laminae of the five lumbar vertebrae slopes in an anterosuperior direction (fig. 1). The laminae, unlike in the thoracic spine, do not overlap, and there is

a distinct interlaminar space between adjacent vertebrae. The spinous processes are broad and flat in the vertical dimension and project posteriorly, with only a slight inferior angulation. Thus, accessing the vertebral canal in the midline *via* the interspinous and interlaminar spaces is relatively easy. These spaces are further enlarged by forward flexion.²⁶ Midline access can be more difficult in the elderly because of narrowing or calcification of the interspinous space, heterotopic ossification of the interspinous ligaments,²⁷ and hypertrophy of the facet joint. The transverse processes arise anterior to the articular processes and project posterolaterally; the L3 transverse process is characteristically the longest.²⁴ The facet joints and transverse processes lie in approximately the same transverse plane as the interlaminar space, and the inferior edge of the spinous process overlies the widest part of the interlaminar space.

The ligamentum flavum arches over the interlaminar space; deep to it lies the fat-filled compartment of the posterior epidural space (fig. 2). The posterior epidural space has a triangular cross-section (typically 7 mm wide in the midline anteroposterior dimension) in the lumbar region and narrows away to a virtual space anterior to the laminae, where the posterior dura lies in direct contact with bone.²⁵ Within the thecal sac, the conus medullaris in the adult is most often

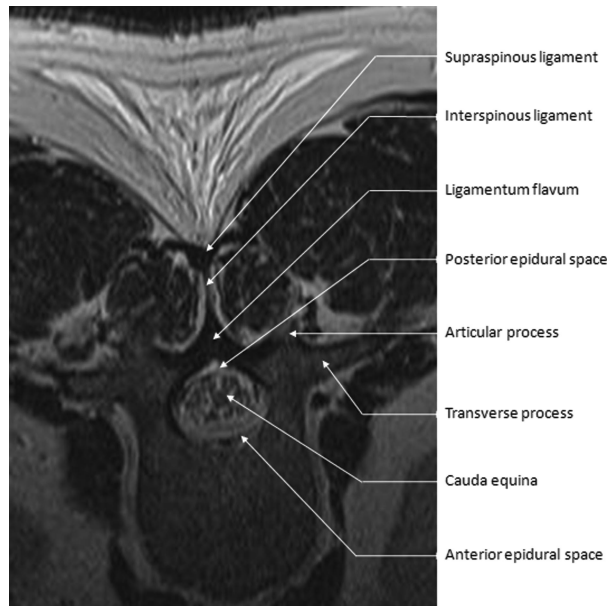


Fig. 2. Transverse (axial) magnetic resonance imaging (MRI) view of a lumbar vertebra at the level of the interlaminar space. In this T1-weighted image, fat (subcutaneous tissue, epidural space), and fluid appear white; connective tissue (ligaments, dura) and muscle appear dark. The vertebral canal contains the epidural space, thecal sac (seen as a dark outline between epidural space and cerebrospinal fluid), and cauda equina. Note the arch-like structure of the ligamentum flavum and the triangular cross-section of the posterior epidural space immediately deep to it. (Image used with permission from www.usra.ca.)

located at the level of the first lumbar (L1) vertebral body; however, its location in any individual patient follows a normal distribution and may range from the middle of the twelfth thoracic (T12) vertebra to the upper third of L3.²⁸ The conus medullaris gives rise to the cauda equina and filum terminale. The thecal sac typically ends at the midpoint of the second sacral vertebra (S2), although in the individual patient this can range from the upper border of S1 to the lower border of S4.²⁹

Sonographic Technique and Sonoanatomy

Preparation for Scanning. During scanning of the lumbar spine, patients should be placed in the position in which the block is to be performed; this is usually the lateral decubitus or sitting position. We recommend a curved-array, low-frequency (2–5 MHz) probe because the wide field of view and deeper penetration improve recognition of anatomy and image quality, respectively. An initial depth setting of 7–8 cm is appropriate for most patients, but the depth, focus, and gain settings of the ultrasound machine should be adjusted as needed during the scanning process to produce an optimal image.

Anatomic Planes and Planes of Ultrasound Imaging. Human anatomy is characteristically described in terms of three basic planes: sagittal, transverse, and coronal (fig. 3). Similarly, there are three basic orientations of the ultrasound probe and beam: (1) paramedian sagittal (PS), when the beam is oriented in the sagittal plane of the spine lateral to the median (midline) sagittal plane; (2) paramedian sagittal oblique (PS oblique), similar to the PS plane except that the beam is now tilted and aimed toward the median sagittal plane; and (3) transverse, when the beam is orientated parallel to the transverse or horizontal plane. The terms “transverse” and “axial” are synonymous when referring to imaging planes; we shall be using the former term throughout this review.

Ultrasonographic Views of the Spine. Pattern recognition is essential in interpreting spinal sonoanatomy because the depth and limited acoustic windows often preclude clear visualization of the relevant anatomic structures. It is worth remembering that bony surfaces appear as hyperechoic (white) linear structures with dense acoustic shadowing (black) beneath that completely obscures any deeper structures. Connective tissue structures, such as ligaments and fascial membranes, also are hyperechoic; however, their acoustic impedance is less than that of bone, so deeper structures can still be imaged. Fat and fluid have very low acoustic impedance and are hypoechoic (dark). A systematic approach to scanning (table 1) facilitates both the process of pattern recognition and the overall performance of ultrasound-guided neuraxial blockade. There are five basic ultrasonographic views that may be obtained, and these are described here in detail.

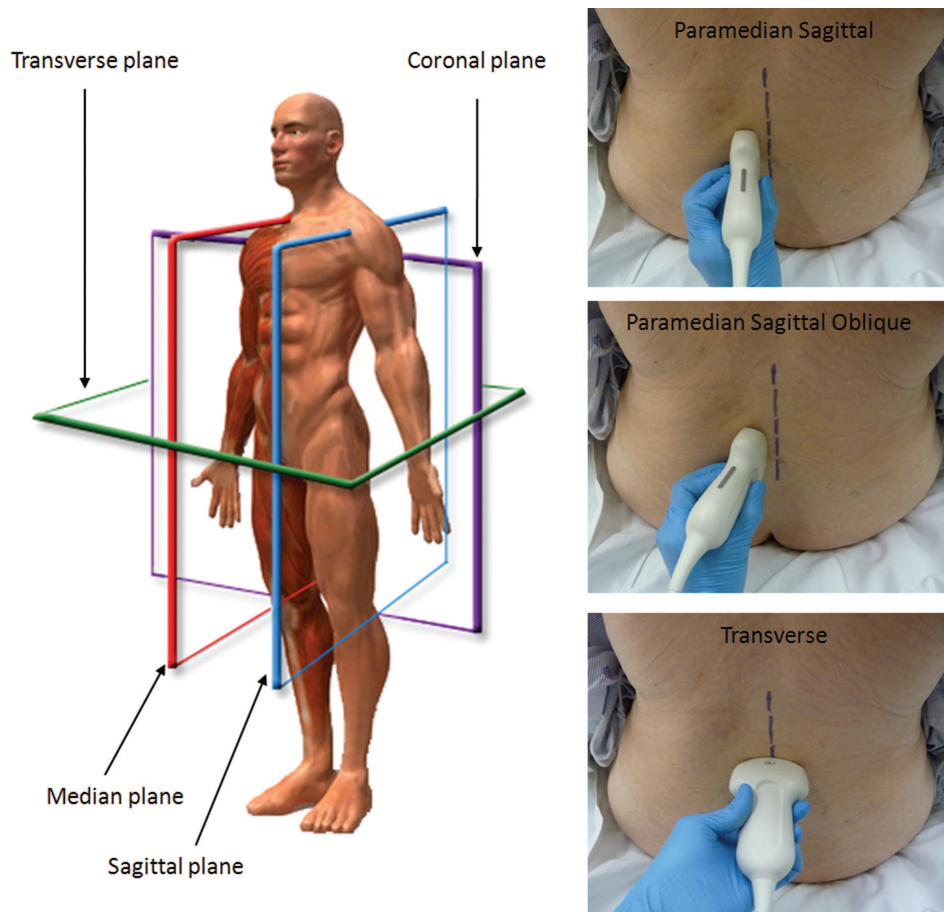


Fig. 3. Anatomic planes and ultrasound probe orientations. There are three primary anatomic planes of the human body: sagittal, transverse, and coronal. The midline sagittal plane is also known as the median plane. The three basic ultrasound probe orientations are named for the anatomic plane in which the beam travels: paramedian sagittal, paramedian sagittal oblique, and transverse. The *dashed line* marks the patient's midline. (Image used with permission from www.usra.ca.)

1. PS Transverse Process View. To start, the ultrasound probe is placed in a PS orientation 3–4 cm lateral to the midline and just above the upper border of sacrum. In this view, the transverse processes of successive lumbar vertebrae are visualized. These appear as short hyperechoic curvilinear structures with pronounced “finger-like” acoustic shadowing beneath, an appearance that has been described as the “trident sign.”³⁰ The striated psoas major muscle is visible between the acoustic shadows and deep to the transverse processes (fig. 4).

2. PS Articular Process View. From the PS transverse process view, the probe is slid medially until a continuous hyperechoic line of “humps” is seen (fig. 5). In this PS articular process view, each hump represents the facet joint between a superior and inferior articular process of successive vertebrae. Both the superior and inferior articular processes lie in the coronal plane posterior to the transverse processes and thus are seen at a more superficial depth than are the transverse processes.

3. PS Oblique View. Once the PS articular process view has been obtained, the probe is tilted to angle the beam in a

lateral-to-medial direction toward the median sagittal plane. The sloping hyperechoic laminae of the lumbar vertebrae form a “sawtooth”-like pattern in this view. The intervening gaps represent the paramedian interlaminar spaces, through which the following structures may be visualized (in order, from superficial to deep): ligamentum flavum, epidural space, posterior dura mater, intrathecal space, anterior dura, posterior longitudinal ligament, and posterior vertebral body (fig. 6).

The ligamentum flavum, epidural space, and posterior dura often appear as a single linear hyperechoic structure, which we have termed the posterior complex. Small sliding and tilting movements of the probe may allow the ligamentum flavum and posterior dura to be distinguished as two hyperechoic lines separated by the hypoechoic fat-filled posterior epidural space. However, the posterior epidural space may not always be visible. This is partly explained by the limitations of ultrasound resolution, particularly in obese patients, but also by the posterior epidural space being triangular in cross section.²⁵ It thins significantly toward its lateral margins, so its apparent

Table 1. Systematic Approach to Ultrasound-guided Neuraxial Blockade of the Adult Lumbar Spine

Steps	Process	Key US Landmarks
1. Preparation for scanning	Place patient in the position in which block will be performed. Select a low-frequency (e.g., 2–5 MHz), curved-array US probe. Adjust depth (usually 7–10 cm), focus, and gain settings on the US machine as required.	
2. PS transverse process view	Place probe in a PS orientation 3–4 cm from the midline.	Trident sign, represented by the finger-like acoustic shadows of the transverse processes
3. PS articular process view	Slide the probe medially toward the midline while maintaining a PS orientation.	Rounded “humps” of the facet joints between superior and inferior articular processes
4. PS oblique view	Having obtained the PS articular process view, tilt the probe toward the midline to obtain the PS oblique view. Additional small sliding and tilting movements of the probe may be required to optimize the view.	“Sawtooth” appearance of the laminae Posterior complex (ligamentum flavum, epidural space and posterior dura) Anterior complex (anterior dura, posterior longitudinal ligament, vertebral body)
5. Identify and mark intervertebral levels	Slide the probe caudad while maintaining a PS oblique orientation, until the L5–S1 intervertebral space is centered on the US screen. Its location will correspond with the midpoint of the probe’s long side and can be marked on the patient’s skin. Slide the probe in a cephalad direction, centering each successive intervertebral space (L4–L5, L3–L4, L2–L3) on the US screen and marking it on the patient’s skin (the “counting-up” approach). The identity of the intervertebral spaces may be confirmed by identifying the T12 vertebra by its articulation with the twelfth rib and then sliding the probe in a caudad direction to visualize each successive intervertebral space (the “counting-down” approach).	Horizontal hyperechoic line of the sacrum The twelfth rib and its articulation with the transverse process of the T12 vertebra
6. Transverse interlaminar view	Rotate the probe 90 degrees into a transverse orientation and slide it cephalad or caudad as required to obtain transverse interlaminar views of the desired interspaces. The probe may have to be tilted in a cephalad direction to optimize the view. Estimate the required needle insertion depth by measuring the depth from skin to the posterior complex using the US machine’s electronic calipers.	Interspinous ligament Articular processes and transverse processes Anterior complex Posterior complex

(continued)

Table 1. Continued

Steps	Process	Key US Landmarks
7. Mark needle insertion point for a midline approach	Center the neuraxial midline on the US screen in the transverse interlaminar view and mark the midpoint of the probe's long and short sides. The intersection of these two markings indicates the needle insertion point. Perform the spinal or epidural anesthetic in the usual fashion, guided by the skin markings and depth measurements. Needle redirections, if required, are usually small and in a cephalad direction.	

PS = paramedian sagittal; US = ultrasound.

width depends on exactly where the ultrasound beam intersects it. The intrathecal space is uniformly hypoechoic, although the cauda equina and filum terminale may be visible as hyperechoic pulsatile streaks within the space. The anterior dura, posterior longitudinal ligament, and posterior aspect of the vertebral body or the intervertebral disc are collectively visible as a single linear hyperechoic

structure (the anterior complex³¹) and are almost never distinguishable from one another in adults.

The superior-inferior dimensions of the interlaminar space may be estimated from the length of the posterior or anterior complex and may provide an indication of the technical difficulty associated with central neuraxial blockade at that level.³² The depth from skin to the pos-

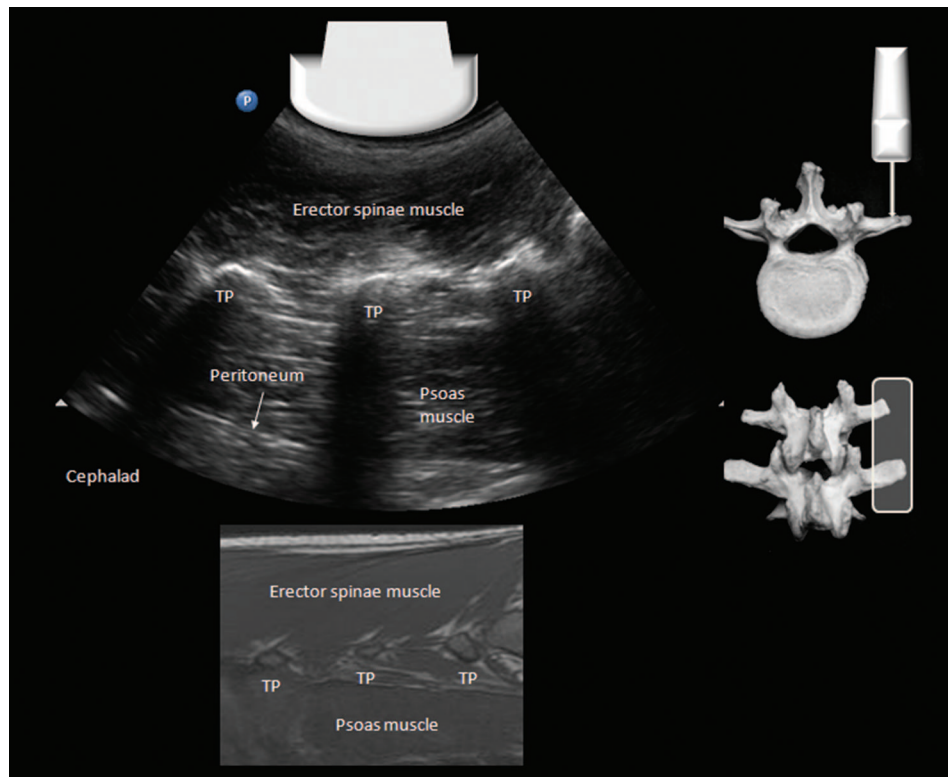


Fig. 4. Paramedian sagittal transverse process view of the lumbar spine and corresponding magnetic resonance imaging (MRI) scan (T1-weighted). The probe is placed over the tips of the transverse processes (TP), which appear as hyperechoic curvilinear structures with “finger-like” acoustic shadowing beneath. This appearance is also called the “trident sign.” The erector spinae muscle and the psoas muscle lie superficial and deep to the transverse processes, respectively. The peritoneum often is visible if the depth setting is increased appropriately. (Image used with permission from www.usra.ca.)

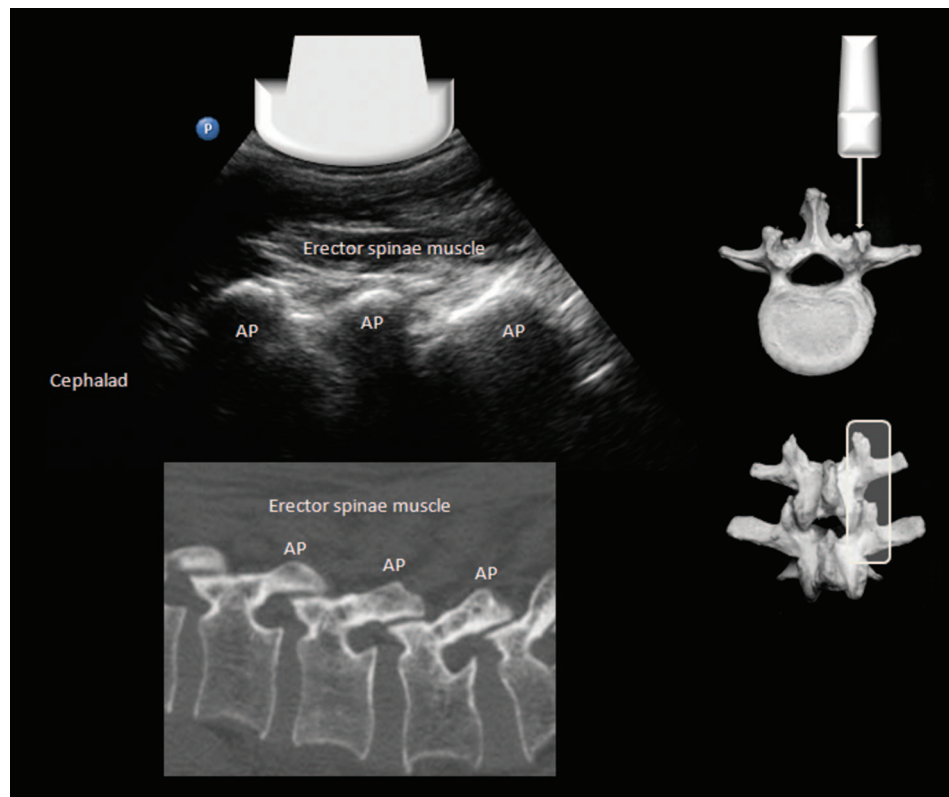


Fig. 5. Paramedian sagittal articular process view of the lumbar spine and corresponding computed tomography image (bone window setting). The overlapping bony superior and inferior articular processes (AP) are seen as a continuous hyperechoic line of “humps” with acoustic shadowing beneath. (Image used with permission from www.usra.ca.)

terior complex may be measured to provide an indication of the expected needle depth for spinal or epidural anesthesia.³³

Accurate identification of intervertebral spaces. While the PS oblique view is maintained, the probe is slid in a caudad direction until the horizontal hyperechoic line of the sacrum comes into view (fig. 7). The gap between the line of the sacrum and the sawtooth of the L5 lamina is the L5–S1 intervertebral space. A characteristic of the L5 lamina is that it is narrower than the other lumbar laminae, and this may facilitate identification. The other lumbar interspaces are readily identified in the PS oblique view by counting upward from the lumbosacral junction. The surface location of each interspace may be indicated by centering it on the ultrasound screen and making a corresponding mark on the skin at the midpoint of the long edge of the probe (fig. 8). This prevents misidentification of the level during later scanning in the transverse plane.

4. Transverse Spinous Process View. Once the examination in the PS plane is completed, the probe is rotated 90 degrees into a transverse orientation and centered on the neuraxial midline. If the probe lies over a spinous process, the tip of the spinous process is visible as a superficial hyperechoic line with acoustic shadowing beneath. Its position may be marked, if desired, by centering it on the

ultrasound screen as described above. The hyperechoic lamina is visible on either side of the spinous process, but all other structures of interest are obscured by bony acoustic shadowing (fig. 9).

5. Transverse Interlaminar View. Sliding the probe in a cephalad or caudad direction from the transverse spinous process view aligns the beam with the interspinous and interlaminar space and provides a transverse interlaminar view of the contents of the vertebral canal. Typically, the linear acoustic shadow of the spinous process gives way to a less dark vertical line (the interspinous ligament framed by the adjacent echogenic erector spinae muscles) and, deep to this, the two parallel hyperechoic lines of the posterior and anterior complex separated by the hypoechoic intrathecal space (fig. 10). Depending on the width of the interspinous space and the angle at which the spinous processes project, the transducer may have to be tilted cephalad to optimize the image of the vertebral canal.

Unlike in the PS oblique view, in the transverse interlaminar view the ligamentum flavum and posterior dura are rarely visible as distinct structures^{14,33,34} and occasionally may not be visible.³⁴ The poorer view of the posterior complex may be attributed to the narrower acoustic window that exists between spinous processes; however, it has also been suggested that absence of the posterior complex is caused by physical gaps in the ligamentum flavum.^{34,35} If the anterior

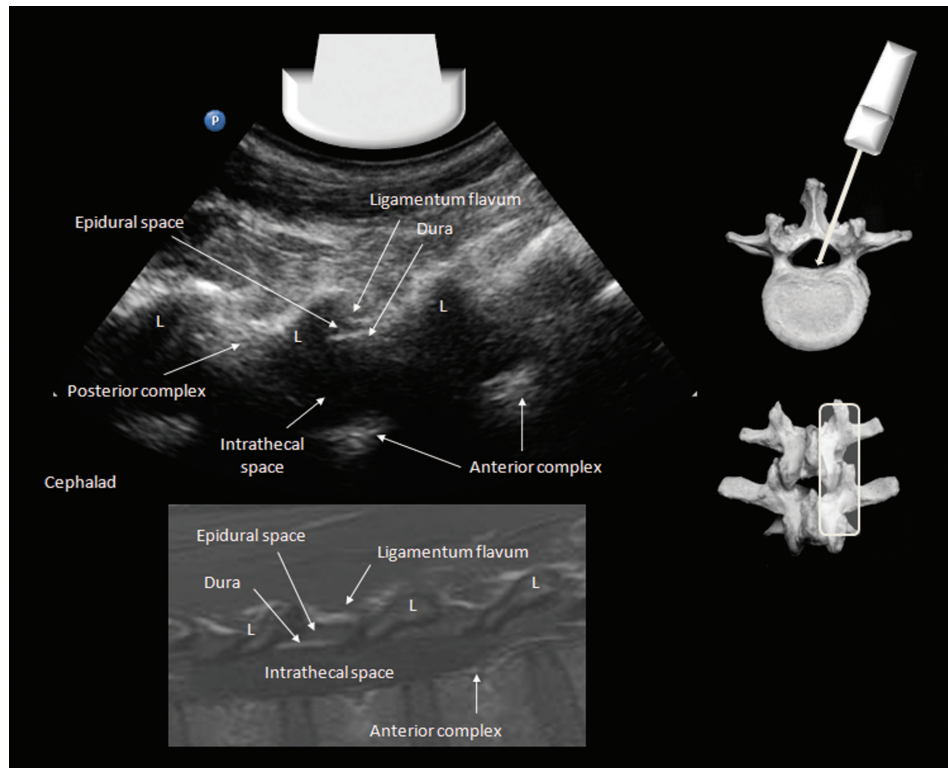


Fig. 6. Paramedian sagittal oblique view of the lumbar spine and corresponding magnetic resonance imaging scan (T1-weighted). The laminae (L) are visible in cross-section as sloping hyperechoic lines with acoustic shadowing beneath. They form a “sawtooth” pattern. The ligamentum flavum, posterior epidural space, posterior dura, and intrathecal space are visible between laminae. Deep to the intrathecal space lie the anterior dura, anterior epidural space, posterior longitudinal ligament, and the posterior aspect of the vertebral body; these usually appear as a single hyperechoic structure, the anterior complex. The ligamentum flavum, posterior epidural space, and dura cannot always be distinguished from one another and may appear as a single hyperechoic structure, the posterior complex. (Image used with permission from www.usra.ca.)

complex is visible, the beam has traversed the vertebral canal, and one can be confident that the interlaminar space has been identified. The transverse processes and articular processes are additional helpful landmarks in difficult cases because they lie in approximately the same transverse plane as the interlaminar space.

Once an optimal view has been obtained, the depth from skin surface to the posterior complex may be measured using the electronic caliper built into the ultrasound machine. The neuraxial midline and the interlaminar space correspond with the midpoint of the long and short sides of the probe, respectively and can be marked on the skin (fig. 8). The intersection of these two landmarks indicates a suitable needle insertion point for a midline approach to spinal or epidural anesthesia. The cephalad angulation required to enter the interlaminar space also can be estimated from the degree of probe tilt required to obtain an optimal transverse interlaminar view.

The Thoracic Spine

Gross Anatomy

The morphology of the 12 thoracic vertebrae varies throughout the length of the thoracic spine. The first four thoracic

vertebrae (T1–T4) are similar to the cervical vertebrae in some respects; they have vertically oriented articular processes and spinous processes that project directly posteriorly. The lowermost four vertebrae (T9–T12) are similar to the lumbar vertebrae; their articular processes project laterally, and their spinous processes are broad, flat, and project directly posteriorly. On the other hand, the spinous processes of T5–T8 vertebrae project posteriorly at an extreme inferior angle, such that the inferior border of the spinous process overlies the midpoint of the lamina of the vertebra below (fig. 11). The laminae of adjacent thoracic vertebrae are also overlapping, making the interlaminar spaces in the thoracic spine extremely small and difficult to access. The thoracic transverse processes arise posterior to the articular processes and articulate with the corresponding rib. The presence of a rib is an identifying feature of the transition between L1 and T12 vertebra and can be used in conjunction with the “counting-up” approach from the L5–S1 junction to determine the intervertebral level.

Sonographic Technique and Sonoanatomy

Sonographic Technique in the Lower Thoracic Spine. The ultrasonographic appearances of the lower thoracic (T9–

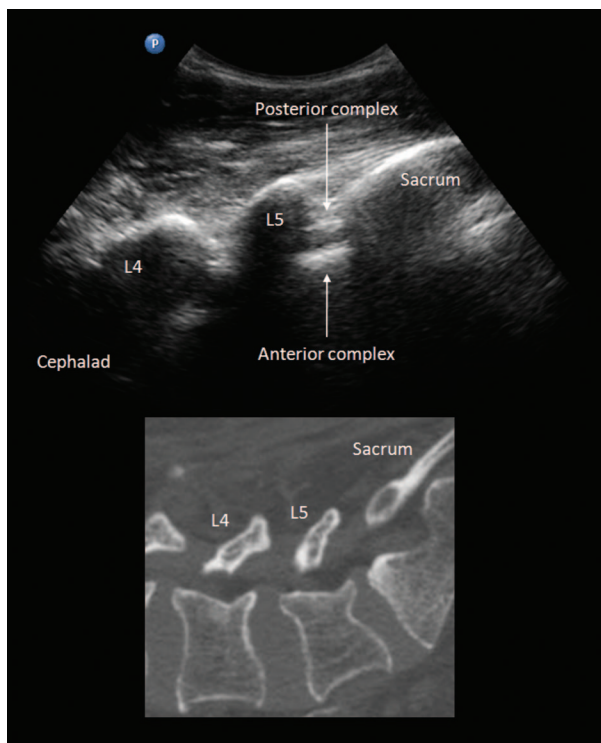


Fig. 7. Paramedian sagittal oblique view of the L5–S1 junction and corresponding computed tomography image (bone window). The sacrum is recognizable as a horizontal hyperechoic curvilinear structure, and the L5 lamina has the typical “sawtooth” appearance. The structures of the vertebral canal are visible through the intervening gap. A distinguishing feature of the L5 lamina is its shorter superior-inferior width compared with the other lumbar vertebrae. (Image used with permission from www.usra.ca.)

T12) vertebrae and the lumbar vertebrae are similar, except that the interlaminar spaces tend to be narrower (fig. 11). With the transducer in a PS orientation 2–3 cm lateral to the midline, the ribs are visible as short hyperechoic lines with pronounced acoustic shadowing beneath. Sliding the transducer medially produces a PS articular process view similar to that of the lumbar spine. The PS oblique and transverse views are then obtained as described in the section on lumbar spine imaging.

Sonographic Technique in the Midthoracic Spine. Imaging in the midthoracic spine is much more difficult because of the extreme caudad angulation of the spinous processes and the overlapping laminae. In practice, we find that although the spinous process, lamina, transverse processes, ribs, and pleura are visible on scanning in the transverse plane, it is nearly impossible to obtain a transverse interlaminar view (fig. 12). Thus, the transverse scan provides very little information relevant to neuraxial blockade apart from identifying the midline and measuring the depth to the lamina. On the other hand, the PS oblique view is more useful. Here, the laminae are visible as horizontal hyperechoic curvilinear structures with acoustic

shadowing beneath, and although the narrow width of the interlaminar space may prevent visualization of the intra-thecal space and anterior complex, the location of the interlaminar spaces can be readily identified and marked in the same manner as for the lumbar region (fig. 13).

Current Evidence for the Clinical Utility and Application of the Ultrasound-guided Technique in Neuraxial Block

Literature Search Strategy and Results

We performed a literature search for relevant studies in the MEDLINE database for the period from its inception until October 22, 2010. We limited search results to human studies in adults (≥ 19 yr). The electronic search strategy contained the following MeSH and free-text terms: (spine OR spinal OR epidural OR neuraxial OR caudal) AND (ultrasound OR ultrasonography OR ultrasonographic) AND (anesthesia OR analgesia OR block). This yielded 875 articles. We reviewed the title, abstract, and as appropriate, the full text of these articles. The reference lists of the selected articles and the authors’ personal file collections also were consulted to identify any studies missed by the electronic search strategy.

This resulted in a list of 55 relevant articles. The breakdown by study type is as follows: 7 review articles,^{6,31,36–40} 5 randomized controlled trials (RCTs),^{8–10,12,41} 27 observational cohort studies,^{2–5,7,13,14,16,33–35,42–57} 14 case reports,^{17,18,32,58–68} and 2 technical articles.^{69,70} Most (62%) of the clinical reports involved obstetric patients. Only three articles pertained to ultrasound imaging of the thoracic spine.^{11,16,63} The methodology and results of the RCTs and observational studies are summarized in tables 2 and 3.

Does the Ultrasound-guided Technique Improve the Clinical Efficacy of Neuraxial Blockade?

Four RCTs compared the ultrasound-guided technique to the conventional surface landmark-guided technique and examined outcomes related to the clinical efficacy of neuraxial blockade.^{8,10,12,41} All involved obstetric patients receiving epidural or combined spinal-epidural anesthesia. In three of these studies,^{8,10,12} interventions and outcomes were performed and assessed by the same (unblinded) investigator; thus, caution is warranted in extrapolating the results. In the largest of these studies¹⁰ ($n = 300$), a significantly lower rate of incomplete analgesia (2 vs. 8%, $P < 0.03$), as well as lower postblock pain scores (scale 0–10, 0.8 ± 1.5 vs. 1.3 ± 2.2 , $P = 0.006$) were seen in the ultrasound-guided group. Patient satisfaction scores were significantly higher in two of the studies,^{8,10} although the differences do not appear to have been clinically important (table 2). Nonsignificant trends to a lower rate of asymmetric block and patchy block were seen in all three studies.

More recently, Vallejo *et al.*⁴¹ randomized 370 parturients receiving labor epidurals into two groups. One group

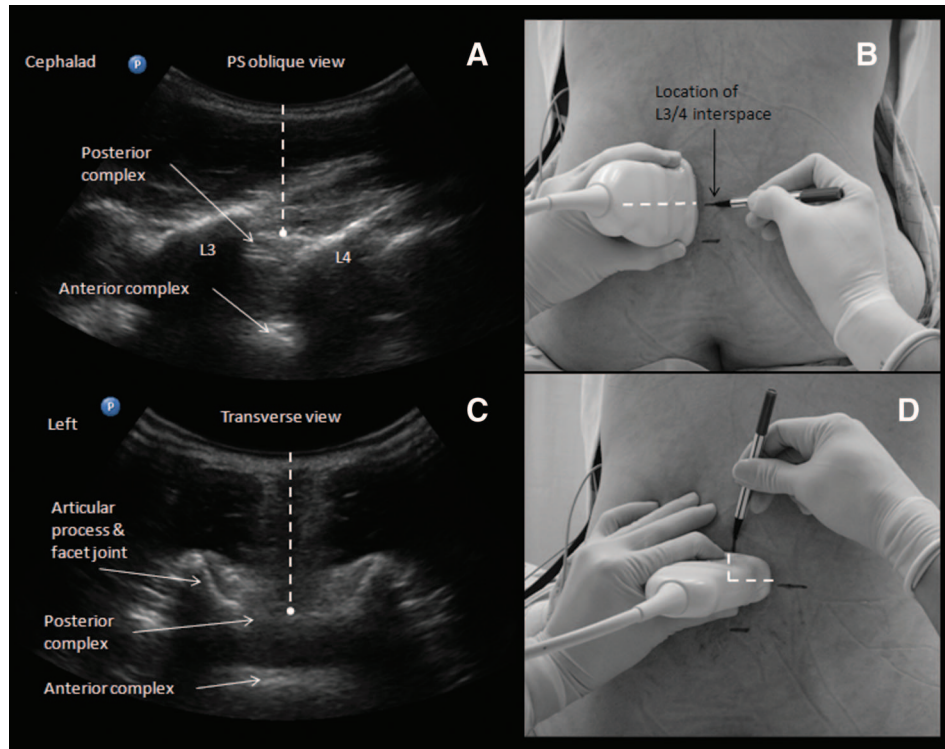


Fig. 8. Surface marking to guide needle insertion. In the paramedian sagittal (PS) oblique view, each interspace (L3–L4 in this case) is centered in turn on the ultrasound screen (A). A corresponding skin mark is made at the midpoint of the probe's long edge (B). The probe is then turned 90 degrees to obtain the transverse interlaminar view (C). The midline is centered on the ultrasound screen, and skin marks are made at the midpoint of the probe's long and short edges (D). The intersection of these two marks provides an appropriate needle insertion point for a midline approach to the epidural or intrathecal space at that level. (Image used with permission from www.usra.ca.)

underwent preprocedural ultrasound imaging of the lumbar spine by a single operator with 6 months' experience in the technique, and the other group did not. All epidurals were performed by a cohort of 15 first-year anesthesiology residents. The information obtained from the ultrasound scan (depth to the epidural space and location of landmarks) was communicated to the resident performing the epidural, who was subsequently supervised by another blinded staff anesthesiologist. The epidural failure rate (defined as inadequate analgesia requiring replacement of the epidural) was significantly lower in the ultrasound-guided group of patients (1.6 vs. 5.5%, $P < 0.02$).

Thus, evidence suggests that the ultrasound-guided technique improves the success and quality of epidural analgesia. However, most of the data originate from a single investigator, and additional randomized trials are needed to establish whether this benefit can be realized by less-experienced practitioners.

Does the Ultrasound-guided Technique Reduce the Technical Difficulty Associated with Neuraxial Blockade?

The technical difficulty of neuraxial blockade may be measured using two parameters: the number of needle manipulations required for success and the time taken to perform the

block. Of the two, we consider the former to be more important because multiple needle manipulations or passes are an independent predictor of complications, such as inadvertent dural puncture, vascular puncture, and paresthesia.⁷¹ In turn, elicitation of paresthesia is a significant risk factor for persistent neurologic deficit after spinal anesthesia.^{72–74} Data from the five RCTs indicate that use of the ultrasound-guided technique either halved the number of needle passes required for successful neuraxial blockade^{8,10,12,41} or significantly increased the first-pass success rate (75 vs. 20%, $P < 0.001$).⁹ In another comparative nonrandomized trial, the success rate of residents learning to perform labor epidurals was significantly increased and accelerated by providing them with information obtained from a preprocedural ultrasound scan.⁵ Again, it should be noted that five of these six studies were conducted by the same investigator and are thus susceptible to bias.

It is only logical that ultrasound would be most helpful in patients with poor or abnormal anatomic landmarks, and this is supported by numerous case reports of successful ultrasound-guided neuraxial block in patients with marked obesity (five reports),^{17,20,62,67,75} previous spinal surgery and instrumentation (seven reports),^{18,59–61,65,66,68} and spinal deformity (four reports).^{16,32,58,63} In one of the five published RCTs, Grau *et al.*⁸ specifically enrolled 72 parturients

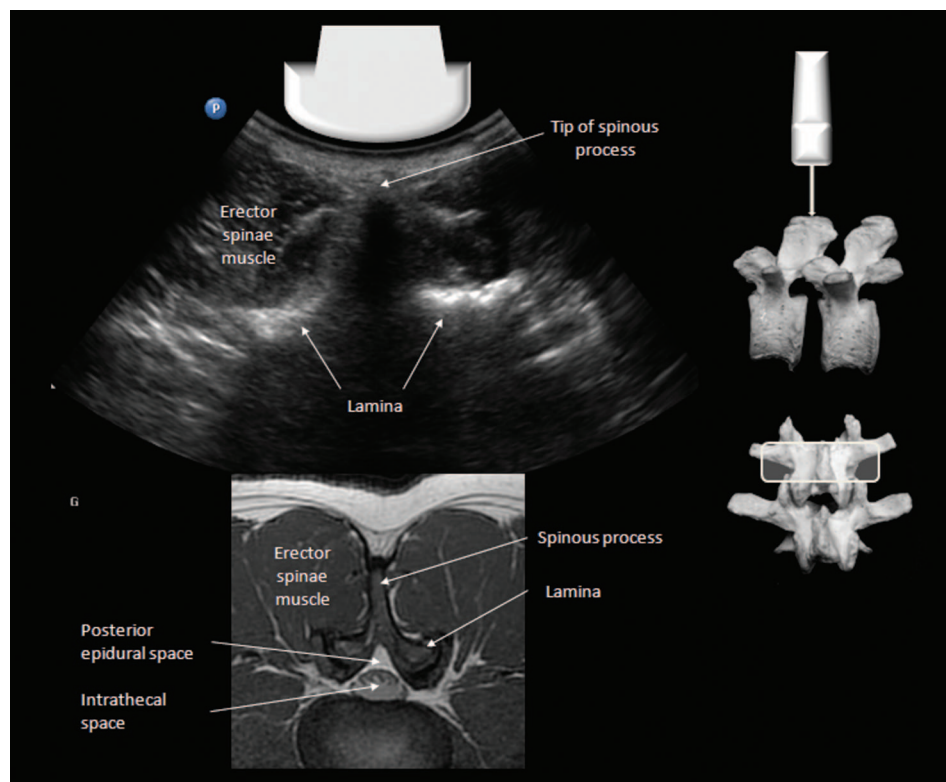


Fig. 9. Transverse spinous process view of the lumbar spine and corresponding magnetic resonance imaging scan (T1-weighted). The tip of the spinous process and the lamina are brightly hyperechoic on ultrasound with pronounced acoustic shadowing that obscures all deeper structures. (Image used with permission from www.usra.ca.)

in whom neuraxial block was anticipated to be difficult because of the presence of spinal deformity, obesity (body mass index more than 33 kg/m^2), or a history of previous difficulty. Patients in whom ultrasound imaging was used underwent fewer needle passes (1.5 ± 0.9 vs. 2.6 ± 1.4 , $P < 0.001$) at fewer spinal interspaces (1.3 ± 0.5 vs. 1.6 ± 0.7 , $P < 0.05$) than did the control group.

The lead author of the present paper recently completed a RCT of ultrasound-guided spinal anesthesia in 120 patients with difficult anatomical landmarks (defined as the presence of poorly palpable surface landmarks and a body mass index $>35 \text{ kgm}^{-2}$, significant spinal deformity, or spinal surgery resulting in distortion or absence of surface landmarks).⁷⁶ This study involved multiple experienced operators, each of whom performed both landmark identification (by palpation or ultrasound) and the spinal anesthetic itself. The primary outcome was the success rate of dural puncture on the first needle insertion attempt (this included needle redirections that did not involve complete withdrawal of the needle from the skin). There was a two-fold difference between the ultrasound-guided group and the control group in the first-attempt success rate (62% vs 32%, $P < 0.001$), and the median number of needle passes required for success (6 vs 13, $P = 0.003$).⁷⁶

In summary, ultrasound imaging of the spine by an experienced operator increases the ease of performance of neuraxial block, particularly in patients in whom difficulty is

anticipated. Ultrasound may also be able to predict the ease of performance of neuraxial block and thus influence clinical decision-making³²; however, this has yet to be systematically investigated.

Can Ultrasound Imaging Accurately Estimate the Required Needle Insertion Depth for Neuraxial Blockade?

Knowledge of the depth from skin to the epidural or intrathecal space allows selection of a needle of appropriate length and may help prevent inadvertent dural puncture. The correlation between ultrasound-measured depth and actual needle insertion depth has been evaluated in multiple studies: 10 in obstetric patients^{2-4,7-9,41,43,44,53} and 3 in nonobstetric patients.^{23,33,45} Correlation was excellent in all studies (Pearson correlation coefficients, 0.80–0.99), whether measurements were made in the sagittal, PS oblique, or transverse views. Of six studies that analyzed the difference between the two depths, the ultrasound-measured depth tended to underestimate actual needle depth in four^{3,33,44,53} and overestimate it in the other two.^{9,43} The 95% confidence limits for the difference ranged from 5 to 15 mm (table 3). Suggested reasons for the discrepancy include differing trajectories of ultrasound beam and needle and tissue compression by the probe during ultrasound scanning (which may cause as much as a 5-mm change in depth⁵²) or by the Tuohy needle during insertion.

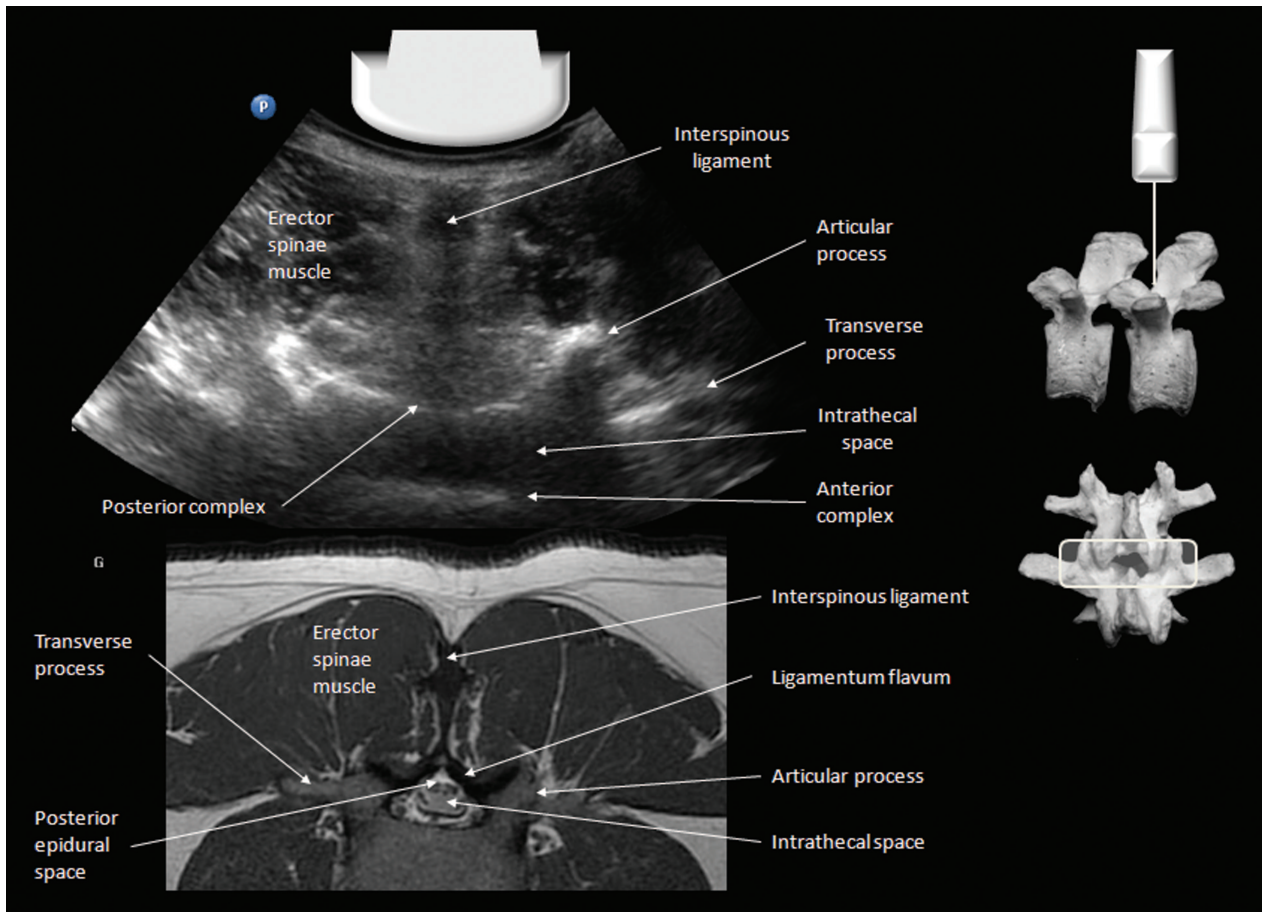


Fig. 10. Transverse interlaminar view of the lumbar spine and corresponding magnetic resonance imaging scan (T1-weighted). The intrathecal space is a dark hypoechoic band sandwiched between the hyperechoic posterior and anterior complex. The transverse processes and articular processes lie in the same transverse plane and are usually visible. The ligamentum flavum, posterior epidural space, and dura often cannot be distinguished from one another in the transverse view. The midline is indicated by the dark vertical stripe of the interspinous ligament. (Image used with permission from www.usra.ca.)

Can Ultrasound Imaging Accurately Identify Intervertebral Levels?

Incorrect identification of the lumbar intervertebral level has been implicated in conus medullaris injury after dural puncture.^{77,78} Although the spinal cord and surrounding cerebrospinal fluid have a similar hypoechoic appearance on ultrasound, the cord and conus medullaris can be identified in the young pediatric population because the outer surface and central canal of the spinal cord are visible as bright hyperechoic lines.^{79,80} These details are not visible in adults because of the greater depth and narrower acoustic windows into the spinal canal, and currently the conus medullaris cannot be localized on ultrasound in adults.

However, ultrasound can identify the intervertebral levels by counting spinous processes or laminae upward from the sacrum; this method is more accurate than clinical estimation using the intercrystal line.⁵⁷ In fact, agreement between clinical and ultrasonographic methods of identifying intervertebral levels has been observed to occur in only 36–55% of cases.^{48,50,55} Both Whitty *et al.*⁵⁵ and Schlotterbeck *et al.*⁵⁰

found that when there was disagreement, the clinically determined level was usually lower than that determined by ultrasound. However, Locks *et al.*⁴⁸ observed that the clinically determined level was higher, rather than lower. Their finding may be explained by their basing clinical identification on the premise that the intercrystal line corresponded to the L4–L5 interspace, but a separate study found that the L3–L4 interspace (as identified on ultrasound) corresponded to the intercrystal line in most subjects.⁴⁹

However, ultrasound is not infallible. Compared with other imaging modalities, such as magnetic resonance imaging,⁵⁴ computed tomography,⁴⁶ and plain radiographs⁵⁷ of the lumbar spine, ultrasound accurately identified a spinous process or intervertebral space only 68–76% of the time. It is worth noting that any inaccuracy observed with ultrasound is likely to be within one interspace of the true level, rather than two or three interspaces, as may occur with palpation of surface landmarks. In addition, two of these three studies used ultrasound technology that would now be considered obsolete,^{54,57} so this may have contributed to misidentifica-

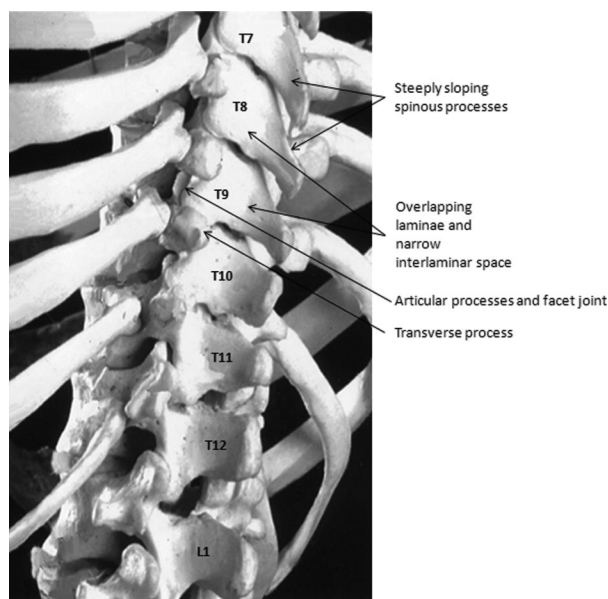


Fig. 11. Gross anatomy of the mid- and lower thoracic spine. The lower thoracic vertebrae (T10–T12) are similar in morphology and ultrasonographic appearance to lumbar vertebrae. The middle thoracic vertebrae have steeply sloping spinous processes that make it impossible to obtain a transverse interlaminar view. The interlaminar spaces are also small, and the paramedian sagittal oblique view into the vertebral canal is limited as a result. (Image used with permission from www.usra.ca.)

tion. Errors are also more likely in the early stages of learning to perform ultrasonography of the spine,^{46,56} and accuracy rates of 90% or greater probably can be achieved with adequate training and experience.⁴⁶ Errors usually result from misidentification of the L5–S1 junction⁵⁶ or failure to recognize developmental anomalies of the lumbosacral junction, which occur in approximately 12% of the general population.⁸¹ Sacralization of the L5 vertebra is most common, in which there is a degree of fusion between L5 and the sacrum involving one or both transverse processes. Less commonly, the S1 vertebra may resemble a lumbar vertebra (lumbarization). Complete sacralization or lumbarization that results in the presence of four or six true lumbar vertebrae, respectively, is a rare occurrence. Definitive diagnosis of lumbosacral transitional vertebrae requires plain radiographs of the spine,⁸¹ which are not always available. However, the accuracy of ultrasound can be enhanced by combining a counting-up approach from the L5–S1 junction with a “counting-down” approach from the T12 vertebra (identified by the presence of the twelfth rib). Although an L1 accessory rib can be present in as much as 2% of the population,⁸² the simultaneous presence of both anomalies is exceedingly rare. Finally, it is reassuring to note that Kim *et al.*⁸³ found the distance between the conus medullaris and Tuffier’s line to be identical in patients with and those without lumbosacral transitional anomalies. Thus, they concluded it is clinically appropriate to count up from the ap-

parent lumbosacral junction when choosing an appropriate level for administration of spinal anesthesia.

What Is the Clinical Utility of the Ultrasound-guided Technique in the Thoracic Spine?

When pertinent structures such as the ligamentum flavum, dura mater, and anterior complex can be visualized in the thoracic spine, it is logical that ultrasonography should have the same utility that it does in lumbar neuraxial blockade. Currently, little has been published about this topic. Grau *et al.* performed an imaging study in 20 volunteers in which they demonstrated it was feasible to identify the pertinent anatomic landmarks with ultrasound imaging.¹¹ However, the authors noted that visualization of the epidural space was much more difficult than that of the lumbar spine, and the PS oblique view was the best for this purpose. The principal limitations of this small study are that only young, slim patients with normal spinal anatomy were included and only the T5–T6 interspace was studied.

As with lumbar neuraxial blockade, the main advantage of the ultrasound-guided technique may be in the patient with abnormal spinal anatomy. The use of ultrasound to delineate spinal anatomy before insertion of an epidural catheter in patients with scoliosis has been described in a single case report and a small case series. Pandin *et al.* used ultrasound to identify a suitable interlaminar window and measure the depth to the epidural space before inserting a midthoracic epidural catheter.⁶³ Accurate placement of the catheter was further confirmed by electric stimulation through the epidural needle and catheter. McLeod *et al.* used ultrasound to measure the degree of axial rotation in the thoracic spine.¹⁶ This was done by placing the transducer in a transverse orientation between spinous processes and manipulating it until the hyperechoic laminae on either side of the midline were level on the ultrasound screen; rotation was then measured as the angle between the long axis of the transducer and the patient’s sagittal plane. The least-rotated interspace was identified and used for epidural insertion *via* a midline approach. Epidural insertion was successful at the chosen interspace in 8 of 11 patients and at the interspace above in the remaining 3. It is notable that a fairly basic ultrasound machine and a linear-array transducer were used in both reports.

In our opinion, even if the vertebral canal is not clearly visible, a preprocedural scan may provide information that will facilitate thoracic epidural catheter insertion. Apart from determining axial rotation (as described by McLeod *et al.*¹⁶), the depth to the lamina may be measured (as a surrogate marker of depth to the epidural space), the levels of the thoracic interspaces may be determined more accurately, and the locations of the midline and interlaminar spaces can be marked on the skin. Triangulation using this information will facilitate estimation of the appropriate needle insertion site and trajectory for a paramedian or midline approach. Currently, no published data support or refute these assertions.

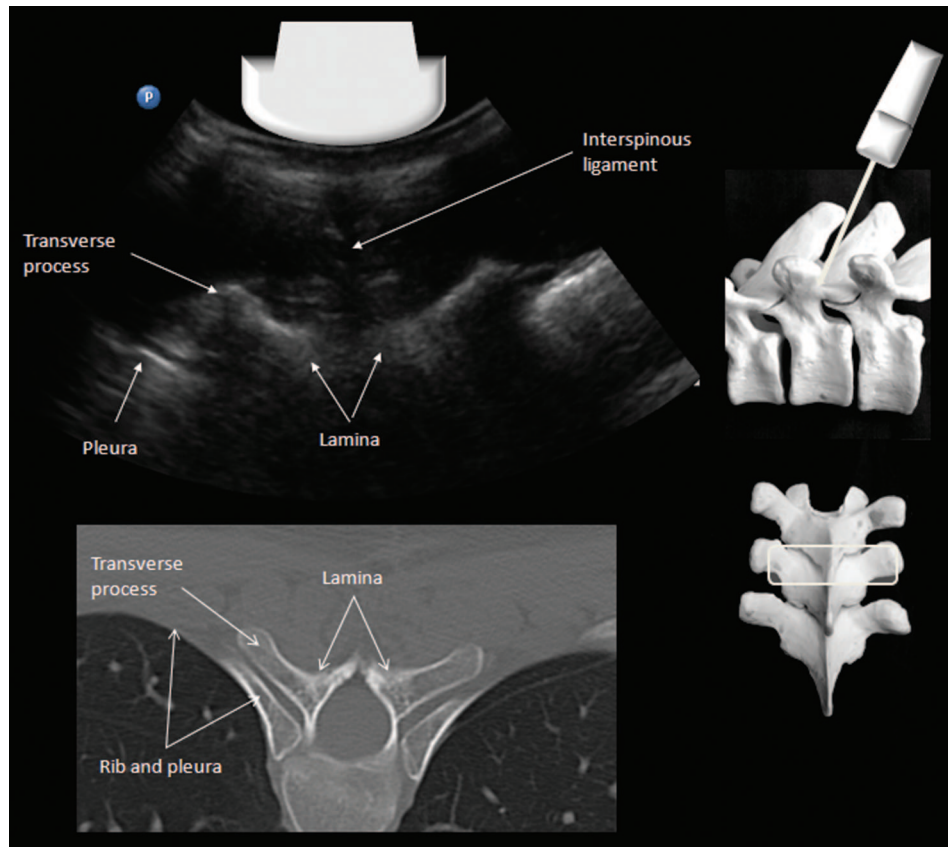


Fig. 12. Transverse interspinous view of the midthoracic spine and corresponding computed tomography image (bone window). An interlaminar view into the vertebral canal cannot be obtained because of the steeply sloping spinous processes and overlapping laminae. (Image used with permission from www.usra.ca.)

What Are the Limitations of the Ultrasound-guided Technique?

Poor Image Quality in Obese and Elderly Patient Populations. Visualization of the deeper structures in the vertebral canal (epidural space, dura, intrathecal space, and anterior complex) can be difficult in certain patient populations.

In obese patients, structures are often less distinct because of the attenuation that occurs as ultrasound waves travel a greater distance through soft tissue. A phase aberration effect caused by the varying speed of sound in the irregularly shaped adipose layers also has been described.⁸⁴ However, advances in imaging technology (*e.g.*, compound imaging and tissue harmonic imaging) can compensate for this deterioration in image quality, and recent studies support the feasibility of ultrasonography in the obese population.^{33,44,76} Simple measures should not be neglected, such as reducing the beam frequency to provide better penetration, adjusting the focus to the appropriate depth, and applying adequate pressure to improve skin-transducer contact and compress the overlying soft tissue. At a minimum, the spinous processes (indicating the midline) and interspinous gaps usually can be identified.⁶⁷ Successful entry into the interlaminar space is more likely if needle redirections from the initial insertion point are made in very small increments. The use of a 22-gauge or larger needle, particularly at lengths of more

than 90 mm, should be considered because such needles are less likely to be deflected from their intended trajectory during insertion.

The problem in elderly patients is narrowing of the interspinous spaces and interlaminar spaces caused by ossification of the interspinous ligaments and hypertrophy of the facet joints, respectively.²⁷ Prominent spinous processes in a thin patient also can hinder adequate skin-probe contact and contribute to poor visualization. In such patients, obtaining a transverse view of the vertebral canal may be physically difficult or impossible, and the PS oblique view may be a better choice. Contact may also be improved by using a probe with a smaller footprint.

Inaccuracy of Skin Marking. There is an inherent degree of inaccuracy when marking the needle insertion point on the skin during the preprocedural scan. Currently available curved-array probes do not have markings that precisely indicate from where the ultrasound beam emanates. There is also an element of tissue distortion when performing the ultrasound scan, particularly in the elderly, who often have loose and mobile skin. Finally, skin marking does not indicate the caudad-to-cephalad angle at which the needle must be advanced in a midline approach. This can be estimated only from the angulation of the probe required to produce an optimal image of the interlaminar space. However, these fac-

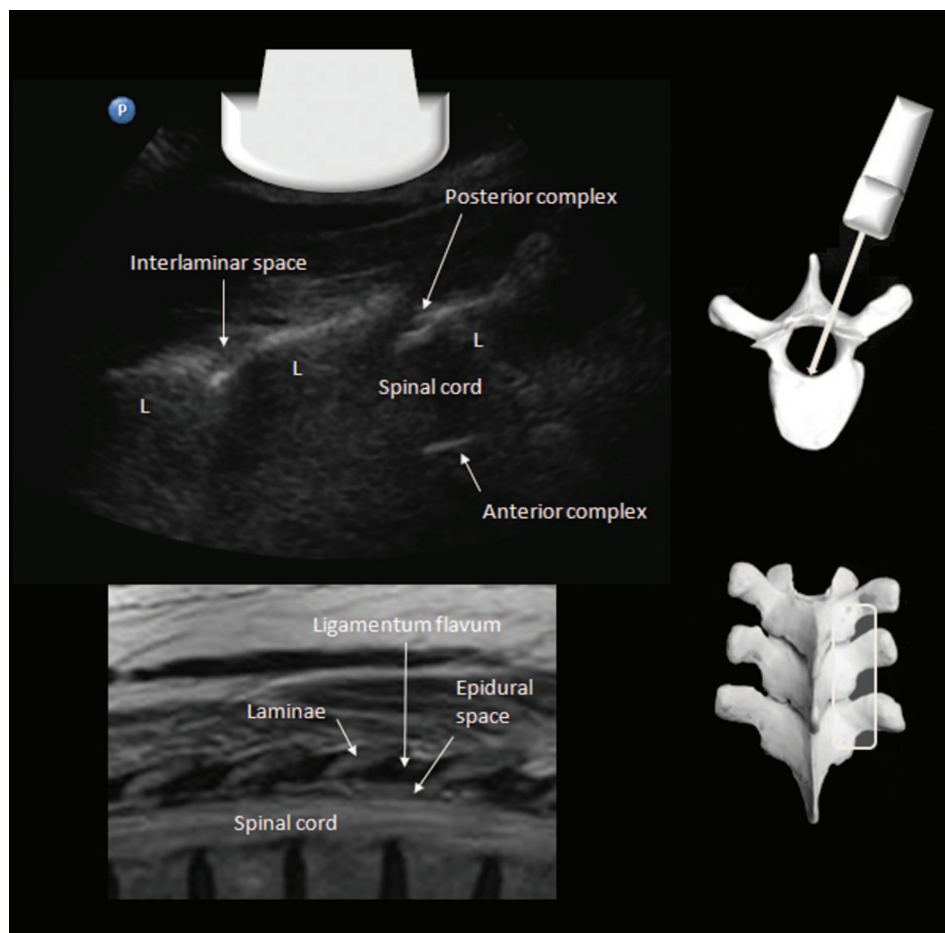


Fig. 13. Paramedian sagittal oblique view of the midthoracic spine and corresponding magnetic resonance imaging scan (T1-weighted). Despite the narrow interlaminar space, it is possible to visualize the posterior and anterior complex at one or more levels. At a minimum, the location of the interlaminar space can be determined by the dip or gap between successive laminae (L). Note that the spinal cord is hypoechoic and is not distinct from the surrounding cerebrospinal fluid. (Image used with permission from www.usra.ca.)

tors can be compensated for by experience with the ultrasound-guided technique.

Is the Ultrasound-guided Technique Easy to Learn?

As a result of these limitations, extensive experience with the ultrasound-guided technique may be required before competence is attained. In virtually all published studies to date, ultrasound imaging has been performed by a small number of experienced investigators.

Two small studies attempted to examine the learning curve associated with ultrasound imaging of the lumbar spine. Margarido *et al.*⁵⁶ recruited 18 anesthesiologists with no previous experience in ultrasound imaging of the spine and provided them with comprehensive training that included reading material, an educational video, a 45-min lecture, and a 30-min hands-on workshop. The subjects were assessed 7–14 days later on their ability to perform three tasks in a human volunteer with normal (“easy”) anatomy: identify lumbar intervertebral spaces, mark an optimal insertion point, and measure the depth to the epidural space. Accuracy

was determined by comparing their performance with that of three experts. Each subject performed as many as 20 consecutive trials, and cusum analysis was used to determine whether competence was achieved. Only five (27%) subjects achieved competence in identifying the intervertebral spaces; none demonstrated competence at the other two tasks. However, these results are inconclusive because only 11 (61%) of the subjects managed to complete 20 trials in the allotted time of 1 h. The criteria for success were also very strict, and the authors noted that most of the errors did not stem from an inability to recognize the relevant anatomy, but rather from imprecision in skin marking and depth measurement. They concluded that these errors could have been avoided by greater meticulousness on the part of the operator.

Halpern *et al.*⁴⁶ also used cusum analysis to determine the learning curve associated with using ultrasound to identify a given spinous process accurately (subsequently confirmed by computed tomography). They studied two anesthesiologists with no previous experience in ultrasound imaging of the lumbar spine who received training on five patients each. Comple-

Table 2. Randomized and Nonrandomized Comparative Trials

Author/Year	Methodology	Key Results	Comments
Randomized Controlled Trials			
Vallejo <i>et al.</i> 2010 ⁴¹	370 parturients received a labor epidural. Randomized to an US-guided group (n = 189), or a control group (n = 181). An US scan was performed by a single anesthesiologist experienced in US-guided epidurals. The depth to the epidural space, the location of the midline, and the probe angle were communicated to the operator performing the epidural. All epidurals performed by 15 first-year residents under supervision of a blinded staff anesthesiologist.	Clinical efficacy: The epidural failure rate was lower in the US-guided group than in the control group (1.6 vs. 5.5%, <i>P</i> < 0.02). Technical difficulty: Fewer needle passes were required for success in the US-guided group than in the control group (1 vs. 2, <i>P</i> < 0.01). Measurement of depth: There was good correlation between UD and ND in both the PS oblique and transverse views (<i>r</i> = 0.91).	Epidural failure was defined as inadequate analgesia requiring replacement of the epidural during labor. A needle pass was defined as any forward advancement of the needle. A single operator performed all US scans.
Grau <i>et al.</i> 2004 ¹²	30 parturients received CSE for LSCS. Randomized to one of three groups (n = 10 each): a control group; a group that received a preprocedural US scan with a linear transducer to determine optimal insertion point, trajectory, and depth to epidural space; and a group that had the CSE performed using a real-time, two-operator, US-guided freehand technique.	Clinical efficacy: Asymmetric block was observed in one patient in the control group, but not in the other two groups (NS). Patchy block was observed in one patient in the control group, but not in the other two groups (NS). There was no difference in intraoperative pain scores or patient satisfaction between groups. Technical difficulty: Success rate on the first needle pass was 100% in the real-time US-guided group vs. 70% in the pre-procedural US group vs. 40% in the control group.	A needle pass was defined as any forward advancement of the needle. A single operator performed all procedures, except in the real-time US-guided technique, for which an assistant held the transducer. There was no blinded independent outcome assessor.
Grau <i>et al.</i> 2002 ¹⁰	300 parturients received an epidural for labor or LSCS. Randomized to an US-guided group (n = 150), or a control group (n = 150). An US scan was performed to determine the optimal level for insertion and to measure the depth to the epidural space. Both the US scan and epidural were performed by a single experienced operator.	Clinical efficacy: Epidural failure was observed in two patients in the control group but not in the US-guided group (NS). The rate of incomplete analgesia/anesthesia was lower in the US-guided group than in the control group (2 vs. 8%, <i>P</i> < 0.03). Asymmetric block was observed in fewer patients in the US-guided group than in the control group (0.7 vs. 2%, NS).	Epidural failure and incomplete analgesia/anesthesia were not clearly defined. A single operator performed all procedures. There was no blinded independent outcome assessor.

(continued)

Table 2. Continued

Author/Year	Methodology	Key Results	Comments
		<p>Postblock pain scores were lower in the US-guided group than in the control group (0.8 ± 1.5 vs. 2.2 ± 1.1, $P = 0.006$).</p> <p>Patient satisfaction (scale 1–6, 1 = best, 6 = worst) was higher in the US-guided group than in the control group (1.3 ± 0.5 vs. 1.8 ± 0.9, $P < 0.001$).</p> <p>Technical difficulty: Fewer needle passes were required for success in the US-guided group than in the control group (1.3 ± 0.6 vs. 2.2 ± 1.1, $P = 0.013$).</p> <p>Measurement of depth: There was good correlation between UD and ND ($r = 0.83$).</p>	
Grau <i>et al.</i> 2001 ⁹	<p>80 parturients received a CSE for LSCS.</p> <p>Randomized to an US-guided group ($n = 40$), or a control group ($n = 40$).</p> <p>An US scan was performed to determine the optimal level for insertion and measure the depth to the epidural space.</p> <p>Both the US scan and CSE were performed by a single experienced operator.</p>	<p>Technical difficulty: Success rate on the first needle pass was higher in the US-guided group than in the control group (75 vs. 20%, $P < 0.001$).</p> <p>Measurement of depth: There was good correlation between UD and actual ND ($r = 0.92$).</p> <p>The mean (UD-ND) difference was 5.1 ± 2.6 mm.</p>	<p>A single operator performed all procedures.</p> <p>There was no blinded independent outcome assessor.</p>
Grau <i>et al.</i> 2001 ⁸	<p>72 parturients were expected to have a difficult labor epidural for the following reasons: history of previous difficulty (36%), spinal deformity (26%), BMI > 33 kg/m² (38%).</p> <p>Randomized to a US-guided group ($n = 36$) or a control group ($n = 36$).</p> <p>An US scan was performed to determine the optimal level for insertion and measure the depth to the epidural space.</p> <p>Both the US scan and CSE were performed by a single experienced operator.</p>	<p>Clinical efficacy: Epidural failure was observed in two patients in the control group but not in the US-guided group (NS).</p> <p>Asymmetric block was observed in fewer patients in the US-guided group than in the control group (5.5 vs. 14.7%, NS).</p>	

(continued)

Table 2. Continued

Author/Year	Methodology	Key Results	Comments
		<p>Patchy block was observed in fewer patients in the US-guided group than in the control group (2.7 vs. 8.8%, NS).</p> <p>Post-block pain scores were lower in the US-guided group than in the control group (0.8 ± 1.4 vs. 1.8 ± 2.7, $P < 0.035$).</p> <p>Patient satisfaction (scale 1–6, 1 = best, 6 = worst) was higher in the US-guided group than in the control group (1.3 ± 0.5 vs. 2.1 ± 1.3, $P < 0.006$).</p> <p>Technical difficulty: Fewer needle passes were required for success in the US-guided group than in the control group (1.5 ± 0.9 vs. 2.6 ± 1.4, $P < 0.001$).</p> <p>Measurement of depth: There was good correlation between UD and ND ($r = 0.87$).</p>	<p>Epidural failure was not clearly defined.</p> <p>The distribution of reasons for difficulty between groups was not reported.</p> <p>A single operator performed all procedures.</p> <p>There was no blinded independent outcome assessor.</p>
Non-randomized Comparative Trials Grau <i>et al.</i> 2003 ⁵	<p>10 residents performed their first 60 labor epidurals, supervised by a single anesthesiologist who did not intervene unless they failed. The residents were divided into two groups: a control group (n = 5), and an US-guided group (n = 5). Residents in the US-guided group were given information on the optimal needle insertion point and trajectory and the measured depth to the epidural space. The US scan was performed by a single experienced operator who was also responsible for supervising the residents and assessing study outcomes.</p>	<p>Technical difficulty: Success rate for the first 10 epidurals was higher in the US-guided group than in the control group ($86 \pm 15\%$ vs. $60 \pm 16\%$, $P < 0.001$).</p> <p>Success rate for the first 60 epidurals remained higher in the US-guided group ($94 \pm 9\%$ vs. $84 \pm 15\%$, $P < 0.001$).</p>	<p>Success was defined as adequate analgesia with three attempts or less at a single level.</p> <p>A single operator performed all US scans.</p> <p>There was no blinded independent outcome assessor.</p>

BMI = body mass index; CSE = combined spinal-epidural; LSCS = lower segment caesarean section; PS = paramedian sagittal; ND = actual needle insertion depth; NS = not significant; UD = ultrasound-measured depth to the epidural space; US = ultrasound.

Table 3. Observational Cohort Studies

Author/Year	Methodology	Key Results	Comments
Technical Difficulty and Measurement of Depth			
Balki <i>et al.</i> 2009 ⁴⁴	46 obese patients (median BMI 40, range 33–86 kg/m ²). US was used to identify and mark the L3–L4 space and to measure depth to the epidural space. Visual quality of the posterior complex was also assessed. An epidural was performed by a second operator who was guided by the skin markings but unaware of the US-measured depth.	Technical difficulty: Success rate on first needle pass was 67%. Success rate on first needle insertion was 76%. The visual quality of the posterior complex was good in 63%, fair in 28%, poor in 9%. Measurement of depth: There was good correlation between UD and ND ($r = 0.85$). UD tended to underestimate ND; mean (ND – UD) difference was 3 mm (95% CI, –7–13 mm).	A “needle insertion” was defined as a one involving a new skin puncture and did not include change in needle trajectory without complete withdrawal from the skin. A “needle pass” was defined as any forward advancement of the needle.
Tran <i>et al.</i> 2009 ⁵³	20 patients. US was performed by an experienced sonographer and used to measure depth to the epidural space in the PS oblique view. An epidural was performed by a second operator using a midline approach.	Measurement of depth: Good correlation between UD to the epidural space in the PS oblique view and ND ($r = 0.80$). US tended to underestimate ND; mean (UD – ND) difference was –4.8 mm (95% CI, –14.8–5.2 mm).	It is unclear whether the epiduralist was blinded to results of the US scan. Depth to the epidural space was measured as depth to the dorsal, rather than ventral, surface of the posterior complex.
Chin and Chan 2009 ³²	50 patients received spinal anesthesia for total joint arthroplasty. A US scan was performed to determine the optimal needle insertion point and measure the depth to the intrathecal space. The same operator performed spinal anesthesia at the chosen interspace using a midline approach.	Technical difficulty: Success rate on first needle insertion was 84% (42 of 50). Success rate on first needle pass was 52% (26 of 50). Measurement of depth: There was good correlation between UD and ND ($r = 0.86$). UD tended to underestimate ND; mean (ND – UD) difference was 2.1 mm (95% CI, –8.5–12.7 mm).	A needle insertion was defined as a one involving a new skin puncture and did not include change in needle trajectory without complete withdrawal from the skin. A needle pass was defined as any forward advancement of the needle. A single experienced operator performed both the US scan and spinal anesthetic in all patients.
Arzola <i>et al.</i> 2007 ⁴³	61 patients. US was used to identify and mark a suitable interspace and measure depth to the epidural space. An epidural was performed by a second operator who was aware of the information obtained from US.	Technical difficulty: Success rate on first needle pass was 73.7%. Success rate on first needle insertion was 91.8%. Measurement of depth: There was good correlation between UD and ND ($r = 0.89$). UD tended to slightly overestimate ND; mean (UD – ND) difference was 0.1 mm (95% CI, –6.7–6.9 mm).	A needle insertion was defined as a one involving a new skin puncture and did not include change in needle trajectory without complete withdrawal from the skin. A needle pass was defined as any forward advancement of the needle.

(continued)

Table 3. Continued

Author/Year	Methodology	Key Results	Comments
McLeod <i>et al.</i> 2005 ¹⁶	11 patients received an epidural for corrective scoliosis surgery. A US scan was performed with a linear transducer to determine the thoracic interspace with the least degree of axial rotation. An epidural was inserted at this interspace by a senior trainee using a midline approach and a conventional landmark-guided technique.	Technical difficulty: Epidural insertion was successful at the chosen interspace in 73% of cases and at the space above in the remaining 27%.	A single operator performed all the US scans; experience level was not reported.
Grau <i>et al.</i> 2001e ⁷	100 patients. A single operator performed a US scan of the L3–L4 interspace before labor epidural insertion. The UD was measured and correlated with ND.	Measurement of depth: There was good correlation between UD and ND ($r = 0.79$).	Study published in German.
Bonazzi <i>et al.</i> 1995 ⁴⁵	40 patients received an epidural for inguinal hernia repair. A US scan was performed to measure UD in the sagittal view. This was correlated with ND.	Measurement of depth: There was good correlation between UD and ND ($r = 0.99$).	Study published in Italian.
Wallace <i>et al.</i> 1992 ⁴	36 obese patients received an epidural for LSCS. An US scan was performed with a linear transducer using transverse and sagittal views. UD was measured and correlated with ND.	Measurement of depth: Linear regression analysis showed that ND could be predicted from the US measurement.	The ultrasound technology was fairly primitive, and image quality was poor as a result. The BMI of subjects ranged from 34.1 to 69.8 kg/m ² . The number, identities, and experience level of the investigators performing the US scans and the epidural were not reported. There was no mention of blinding.
Currie 1984 ³	75 parturients received a labor epidural. An US scan was performed with a linear transducer using the sagittal view. The depth to the lamina on US was measured and correlated with ND. The epidural was performed by a second operator blinded to the results of US scan.	Measurement of depth: There was good correlation between US-measured depth to the lamina and (ND) ($r = 0.96$). US underestimated ND in 74 of 75 cases. The lamina was not visible in one case.	The ultrasound technology was fairly primitive, and image quality was poor as a result. The number, identities, and experience level of the investigators performing the US scans were not reported.

(continued)

Table 3. Continued

Author/Year	Methodology	Key Results	Comments
Cork <i>et al.</i> 1980 ²	36 patients received epidural analgesia. An US scan was performed with a linear transducer to measure the depth to the lamina and ligamentum flavum in the sagittal and transverse planes. This was correlated with ND. The epidural was performed by a second blinded operator.	Measurement of depth: There was good correlation between UD and ND ($r = 0.98$).	The ultrasound technology was primitive, and image quality was poor as a result. The number, identities, and experience level of the investigators performing the US scans were not reported.
Identification of Intervertebral Levels			
Locks <i>et al.</i> 2010 ⁴⁸	90 patients. The L3–L4 interspace was identified and marked using the intercrystal line by an operator with more than 5 yr experience in obstetric anesthesia. An US scan was performed to identify the L3–L4 interspace.	Identification of intervertebral level: Agreement was seen in 51% of cases. Compared with the US-identified interspace, the clinically identified interspace was 1 level lower in 3%, 1 level higher in 40%, and 2 levels higher in 6% of patients.	The intercrystal line was assumed to correspond to the L4–L5 interspace. The identity and experience of the ultrasonographer were not stated.
Pysyk <i>et al.</i> 2010 ⁴⁹	114 volunteers. A US scan was performed to identify the interspace corresponding to the intercrystal line.	Identification of intervertebral level: The intercrystal line corresponded to L2–L3 in 13%, L3–L4 in 73%, and L4–L5 in 14% of subjects. The intercrystal line was more likely to correspond to L2–L3 in men and in taller subjects.	A single operator performed both surface landmark identification and the US scan in all patients.
Schlotterbeck <i>et al.</i> 2008 ⁵⁰	99 patients. Parturients who had a conventional surface landmark-guided labor epidural were scanned during the postpartum period to identify the interspace that had been used. This was correlated with the interspace that had been documented by the operator inserting the epidural.	Identification of intervertebral level: Agreement between the results of the US scan and the documented interspace was seen in 36% of patients. The US-identified interspace was higher than the documented level in 49% and lower than the documented level in 15% of patients.	All US scans were performed by a single operator, whose level of experience was not reported.
Whitty <i>et al.</i> 2008 ⁵⁵	121 patients. Parturients who had a conventional surface landmark-guided labor epidural were scanned during the postpartum period to identify the interspace that had been used.	Identification of intervertebral level: Agreement between the results of the US scan and the documented interspace was seen in 55% of patients.	All US scans were performed by a single operator, whose level of experience was not reported.

(continued)

Table 3. Continued

Author/Year	Methodology	Key Results	Comments
Watson <i>et al.</i> 2003 ⁵⁴	<p>This was correlated with the interspace that had been documented by the operator inserting the epidural.</p> <p>17 patients underwent an MRI scan of the spine.</p> <p>The L3–L4 interspace was identified and marked using a linear US transducer. This was correlated with the L3–L4 space identified on the MRI scan.</p>	<p>The US-identified interspace was higher than the documented level in 32% and lower than the documented level in 12% of patients.</p> <p>Identification of intervertebral level:</p> <p>Agreement between the US-identified and MRI-identified interspace was seen in 76% of patients.</p> <p>In the remaining 24% of patients, the US-identified L3–L4 interspace was located at L2–L3 instead.</p>	<p>A single operator performed all the US scans; the experience level was not reported.</p>
Furness <i>et al.</i> 2002 ⁵⁷	<p>49 patients underwent lumbar spine X-ray.</p> <p>The interspaces between L2 and L5 were identified by surface palpation of landmarks and marked by one of three anesthesiologists.</p> <p>These interspaces were also identified and marked by a radiologist using US.</p> <p>The markings were then correlated with a lateral radiograph of the lumbar spine.</p>	<p>Identification of intervertebral level:</p> <p>Agreement between the US-identified and radiograph-identified interspaces was seen in 71% of cases.</p> <p>Agreement between the clinically identified and radiograph-identified interspaces was seen in 30% of cases.</p> <p>The discrepancy between US-identified and radiograph-identified interspaces was never more than 1 level, whereas the discrepancy between clinically identified and radiograph-identified interspaces was more than 1 level in as many as 27% of cases.</p>	
Scan Quality and Other Outcomes Arzola <i>et al.</i> 2007 ⁴²	<p>41 patients.</p> <p>US was used to measure the anteroposterior diameter of the dural sac in the transverse view at a chosen lumbar interspace.</p> <p>A standardized spinal anesthetic was administered at this space, and the peak sensory block level achieved was determined.</p>	<p>There was no significant correlation between the dural sac diameter and the peak sensory block level.</p>	<p>The number, identities, and experience level of sonographers were not reported.</p>

(continued)

Table 3. Continued

Author/Year	Methodology	Key Results	Comments
Borges <i>et al.</i> 2009 ³⁴	100 patients. A purely descriptive study of the PS oblique and transverse views on ultrasound in term parturients.	Scan quality: The PS oblique view is better than the transverse view for identifying the ligamentum flavum, especially at L4–L5 and L5–S1 interspaces. The ligamentum flavum (posterior complex) was not always clearly visible.	The images were recorded and then analyzed by three investigators.
Lee <i>et al.</i> 2008 ³⁵	36 patients. Case-control study of 18 parturients with unintentional dural puncture and 18 volunteers with history of uneventful epidural. All patients were scanned in the transverse view to characterize the appearance of the ligamentum flavum.	Scan quality: An absent or discontinuous ligamentum flavum was more likely to be seen in the group with unintentional dural puncture (odds ratio 8.21; 95% CI, 3.1–22.0). Abnormal ligamentum flavum was seen most often at the L5–S1 and L4–L5 interspaces.	All US scans were performed by one of three investigators with at least 6 months experience each.
Grau <i>et al.</i> 2001 ¹⁴	60 subjects: 40 volunteers and 20 parturients. A single operator performed an US scan of the lumbar spine in all subjects. The image quality obtained with a 7-MHz linear transducer was compared among three different views: sagittal, PS oblique, and transverse views.	Scan quality: The acoustic window was larger in the PS oblique view than in the sagittal view. Structures were better visualized in the PS oblique view than in the transverse view.	The number, identities, and experience level of the investigators performing the US scans and evaluating the images were not reported.
Grau <i>et al.</i> 2001 ¹³	63 patients. An US scan of the L3–L4 interspace was performed in each patient at two different time points: prior to labor epidural and 250–300 days later. The image quality at these two time points was compared.	Scan quality: There was better visibility of structures, a shallower depth to the vertebral canal, and a larger epidural space in the postpartum period than in the peripartum period.	The number, identities, and experience level of the investigators performing the US scans and evaluating the images were not reported.

(continued)

Table 3. Continued

Author/Year	Methodology	Key Results	Comments
Learning Curve Studies			
Halpern <i>et al.</i> 2010 ⁴⁶	<p>2 anesthesiologists with no experience in US of the spine.</p> <p>An US scan was performed on patients scheduled for CT scan of the abdomen and pelvis. The intervertebral levels were identified in the PS oblique view, and the spinous processes were identified in the transverse view. One spinous process was marked, and its identity was confirmed by a radiologist on the CT scan.</p> <p>The two subjects underwent training on five patients each, and completed US scans on 45 and 29 study patients each. Their competence at identifying a given spinous process was assessed using cusum analysis.</p>	<p>Learning curve:</p> <p>One subject required 36 US scans to attain competence; the other required 22 US scans.</p> <p>Identification of intervertebral level:</p> <p>Agreement between US-identified and CT-identified spinous processes was seen in 68% of cases.</p> <p>The US-identified spinous process was 1 level lower in 5% of cases, 1 level higher in 24% of cases, and 2 levels higher in 3% of cases.</p>	<p>Competence was defined as $\geq 90\%$ accuracy in identifying intervertebral levels as determined by cusum analysis.</p>
Margarido <i>et al.</i> 2010 ⁵⁶	<p>18 anesthesiologists with no experience in US of the spine.</p> <p>Subjects received comprehensive didactic and hands-on training and were assessed 1–2 weeks later on their ability to identify lumbar intervertebral levels, mark an optimal needle insertion point, and measure depth to the epidural space in a single normal volunteer. Each subject performed as many as 20 trials, and competence in each task was assessed using cusum analysis.</p> <p>27% of subjects were able to attain competence in identifying intervertebral levels.</p>	<p>Learning curve:</p> <p>Trials were repeated on the same patient within a space of 1 h and may not reflect real-life learning curves.</p> <p>None of the subjects was able to attain competence in marking a needle insertion point or accurately measuring depth to the epidural space.</p>	<p>Only 61% of subjects completed 20 trials, so much of the analysis was inconclusive.</p>

(continued)

Table 3. Continued

Author/Year	Methodology	Key Results	Comments
Real-time Ultrasound-guided Neuraxial Block			
Tran <i>et al.</i> 2010 ⁵²	19 patients received a CSE for LSCS. This was a feasibility study of a real-time, single-operator, US-guided technique, using an on-screen overlay and fixed-needle guide.	The epidural space was successfully entered in 18 of 19 patients. Limitations included a longer needle track and an inability to access interspaces below L2–L3.	
Karmakar <i>et al.</i> 2009 ⁴⁷	15 patients received epidural or CSE for groin or lower limb surgery. This was a feasibility study of a real-time, single-operator, US-guided freehand technique.	The epidural space was successfully entered in 14 of 15 patients.	

BMI = body mass index; 95% CI = 95% confidence interval; CSE = combined spinal epidural; CT = computed tomography; LSCS = lower segment caesarean section; MRI = magnetic resonance imaging; PS = paramedian sagittal; ND = actual needle insertion depth; NS = not significant; *r* = Pearson correlation coefficient; UD = ultrasound-measured depth to the epidural space or intrathecal space; US = ultrasound.

tence (defined as $\geq 90\%$ accuracy) was achieved by one subject after examination of 22 patients; the other subject required examination of 36 patients before achieving competence.

These preliminary studies suggest that once basic knowledge on ultrasonography of the lumbar spine has been acquired, experience with 40 or more cases may be required to attain competence in scanning. This needs to be confirmed by larger and more robust studies. Additional research is also needed to determine the learning curve associated with the actual performance of a successful ultrasound-guided neuraxial block and optimal training strategies. Novel spine phantom models have been described that permit scanning and needle insertion to be practiced in a workshop setting; however, no data exist to demonstrate how effective these models are at knowledge and skills translation.^{69,70}

Real-time Ultrasound-guided Technique of Lumbar Neuraxial Blockade

Most studies of ultrasound-guided neuraxial blockade have used preprocedural ultrasound imaging. There are only four published reports of lumbar central neuraxial blockade using continuous real-time ultrasound guidance. Grau *et al.*¹² used a two-operator technique; one operator manipulated the transducer in a PS oblique view while the other operator inserted the needle using a midline approach. Karmakar *et al.*⁴⁷ (epidural) and Chin *et al.*⁵⁸ (spinal) reported a single-operator technique in which a PS oblique view of the vertebral canal was obtained and the needle inserted in-plane with the ultrasound beam. In our opinion, the real-time ultra-

sound-guided approach is demanding technically, and more data are required before it can be recommended for routine use. There is also a risk of introducing ultrasound gel into the epidural or intrathecal space, the safety implications of which are unclear. Strategies to prevent this include using gel sparingly (*e.g.*, applied in a thin layer directly onto the probe surface, rather than the patient's skin) and ensuring that the needle insertion site is completely free of gel before puncture or using normal saline instead of gel as the coupling medium. More recently, an experimental technique using an on-screen overlay and fixed-needle guide has been described, which may reduce the difficulty associated with the freehand technique.⁵²

Conclusion

Ultrasound-guided neuraxial blockade is a useful technique that can, among other things, help practitioners more accurately identify intervertebral levels, estimate depth to the epidural space, and locate an appropriate interlaminar space for needle insertion. It is relatively easy to perform using the described systematic approach (table 1), but as with all new techniques, adequate training and clinical experience are required to realize its full potential. At this time, we do not believe the technique should supplant the traditional surface landmark-based techniques of spinal and epidural anesthesia; these are simple, safe, and effective in most patients. Instead, the utility of the ultrasound-guided approach is most evident in patients in whom technical difficulty is expected because of poor surface anatomic landmarks (*e.g.*, in obesity or after spinal surgery) or distorted spinal anatomy (*e.g.*, scoliosis).

The authors gratefully acknowledge the invaluable assistance of Cyrus C. H. Tse, B.Sc., Research Assistant, Department of Anesthesia, Toronto Western Hospital, Toronto, Ontario, Canada, in preparing the figures for this manuscript.

References

1. Bogin IN, Stulin ID: Application of the method of 2-dimensional echospondylography for determining landmarks in lumbar punctures. *Zh Nevropatol Psikhiatr Im S S Korsakova* 1971; 71:1810-1
2. Cork RC, Kryc JJ, Vaughan RW: Ultrasonic localization of the lumbar epidural space. *ANESTHESIOLOGY* 1980; 52:513-6
3. Currie JM: Measurement of the depth to the extradural space using ultrasound. *Br J Anaesth* 1984; 56:345-7
4. Wallace DH, Currie JM, Gilstrap LC, Santos R: Indirect sonographic guidance for epidural anesthesia in obese pregnant patients. *Reg Anesth* 1992; 17:233-6
5. Grau T, Bartussek E, Conradi R, Martin E, Motsch J: Ultrasound imaging improves learning curves in obstetric epidural anesthesia: A preliminary study. *Can J Anaesth* 2003; 50:1047-50
6. Grau T, Conradi R, Martin E, Motsch J: Ultrasound and local anaesthesia. Part III: Ultrasound and neuroaxial local anaesthesia. *Anaesthesist* 2003; 52:68-73
7. Grau T, Leipold R, Conradi R, Martin E, Motsch J: Ultrasonography and peridural anesthesia. Technical possibilities and limitations of ultrasonic examination of the epidural space. *Anaesthesist* 2001; 50:94-101
8. Grau T, Leipold RW, Conradi R, Martin E: Ultrasound control for presumed difficult epidural puncture. *Acta Anaesthesiol Scand* 2001; 45:766-71
9. Grau T, Leipold RW, Conradi R, Martin E, Motsch J: Ultrasound imaging facilitates localization of the epidural space during combined spinal and epidural anesthesia. *Reg Anesth Pain Med* 2001; 26:64-7
10. Grau T, Leipold RW, Conradi R, Martin E, Motsch J: Efficacy of ultrasound imaging in obstetric epidural anesthesia. *J Clin Anesth* 2002; 14:169-75
11. Grau T, Leipold RW, Delorme S, Martin E, Motsch J: Ultrasound imaging of the thoracic epidural space. *Reg Anesth Pain Med* 2002; 27:200-6
12. Grau T, Leipold RW, Fatehi S, Martin E, Motsch J: Real-time ultrasonic observation of combined spinal-epidural anaesthesia. *Eur J Anaesthesiol* 2004; 21:25-31
13. Grau T, Leipold RW, Horter J, Conradi R, Martin E, Motsch J: The lumbar epidural space in pregnancy: Visualization by ultrasonography. *Br J Anaesth* 2001; 86:798-804
14. Grau T, Leipold RW, Horter J, Conradi R, Martin EO, Motsch J: Paramedian access to the epidural space: The optimum window for ultrasound imaging. *J Clin Anesth* 2001; 13:213-7
15. Grau T, Leipold RW, Horter J, Martin E, Motsch J: Colour Doppler imaging of the interspinous and epidural space. *Eur J Anaesthesiol* 2001; 18:706-12
16. McLeod A, Roche A, Fennelly M: Case series: Ultrasonography may assist epidural insertion in scoliosis patients. *Can J Anaesth* 2005; 52:717-20
17. Peng PW, Rofaeel A: Using ultrasound in a case of difficult epidural needle placement. *Can J Anaesth* 2006; 53:325-6
18. Yamauchi M, Honma E, Mimura M, Yamamoto H, Takahashi E, Namiki A: Identification of the lumbar intervertebral level using ultrasound imaging in a post-laminectomy patient. *J Anesth* 2006; 20:231-3
19. National Institute for Health and Clinical Excellence. Ultrasound-guided catheterisation of the epidural space. London: National Institute for Health and Clinical Excellence; 2008
20. Peterson MA, Abele J: Bedside ultrasound for difficult lumbar puncture. *J Emerg Med* 2005; 28:197-200
21. Ferre RM, Sweeney TW: Emergency physicians can easily obtain ultrasound images of anatomical landmarks relevant to lumbar puncture. *Am J Emerg Med* 2007; 25:291-6
22. Nomura JT, Leech SJ, Shenbagamurthi S, Sierzenski PR, O'Connor RE, Bollinger M, Humphrey M, Gukhool JA: A randomized controlled trial of ultrasound-assisted lumbar puncture. *J Ultrasound Med* 2007; 26:1341-8
23. Ferre RM, Sweeney TW, Strout TD: Ultrasound identification of landmarks preceding lumbar puncture: A pilot study. *Emerg Med J* 2009; 26:276-7
24. Cramer GD: *The lumbar region, Basic and Clinical Anatomy of the Spine, Spinal Cord and ANS*, 2nd Edition. Edited by Cramer GD, Darby SA. St. Louis, Mosby, 2005, pp. 242-307
25. Hogan QH: Epidural anatomy: New observations. *Can J Anaesth* 1998; 45:R40-8
26. Cousins MJ, Veering BT: Epidural neural blockade, *Neural Blockade in Clinical Anesthesia and Management of Pain*, 3rd Edition. Edited by Cousins MJ, Bridenbaugh PO. Philadelphia, Lippincott-Raven, 1998; pp 243-320
27. Scapinelli R: Morphological and functional changes of the lumbar spinous processes in the elderly. *Surg Radiol Anat* 1989; 11:129-33
28. Saifuddin A, Burnett SJ, White J: The variation of position of the conus medullaris in an adult population: A magnetic resonance imaging study. *Spine* 1998; 23:1452-6
29. Macdonald A, Chatrath P, Spector T, Ellis H: Level of termination of the spinal cord and the dural sac: A magnetic resonance study. *Clin Anat* 1999; 12:149-52
30. Karmakar MK, Ho AM, Li X, Kwok WH, Tsang K, Ngan Kee WD: Ultrasound-guided lumbar plexus block through the acoustic window of the lumbar ultrasound trident. *Br J Anaesth* 2008; 100:533-7
31. Karmakar MK: Ultrasound for central neuraxial blocks. *Techniques in Regional Anesthesia and Pain Management* 2009; 13:161-70
32. Chin KJ, Chan V: Ultrasonography as a preoperative assessment tool: Predicting the feasibility of central neuraxial blockade. *Anesth Analg* 2010; 110:252-3
33. Chin KJ, Perlas A, Singh M, Arzola C, Prasad A, Chan V, Brull R: An ultrasound-assisted approach facilitates spinal anesthesia for total joint arthroplasty. *Can J Anaesth* 2009; 56:643-50
34. Borges BC, Wieczorek P, Balki M, Carvalho JC: Sonoanatomy of the lumbar spine of pregnant women at term. *Reg Anesth Pain Med* 2009; 34:581-5
35. Lee Y, Tanaka M, Carvalho JC: Sonoanatomy of the lumbar spine in patients with previous unintentional dural punctures during labor epidurals. *Reg Anesth Pain Med* 2008; 33:266-70
36. Carvalho JC: Ultrasound-facilitated epidurals and spinals in obstetrics. *Anesthesiol Clin* 2008; 26:145-58
37. Ecimovic P, Loughrey JP: Ultrasound in obstetric anaesthesia: A review of current applications. *Int J Obstet Anesth* 2010; 19:320-6
38. Grau T: Ultrasound directed punctures in neuro-axial regional anesthesia. *Anesthesiol Intensivmed Notfallmed Schmerzther* 2006; 41:262-5
39. Hotta K: Ultrasound-guided epidural block. *Masui* 2008; 57:556-63
40. Perlas A: Evidence for the use of ultrasound in neuraxial blocks. *Reg Anesth Pain Med* 2010; 35:S43-6
41. Vallejo MC, Phelps AL, Singh S, Orebaugh SL, Sah N: Ultrasound decreases the failed labor epidural rate in resident trainees. *Int J Obstet Anesth* 2010; 19:373-8
42. Arzola C, Balki M, Carvalho JC: The antero-posterior diameter of the lumbar dural sac does not predict sensory levels of spinal anesthesia for Cesarean delivery. *Can J Anaesth* 2007; 54:620-5
43. Arzola C, Davies S, Rofaeel A, Carvalho JC: Ultrasound using the transverse approach to the lumbar spine provides reliable landmarks for labor epidurals. *Anesth Analg* 2007; 104:1188-92
44. Balki M, Lee Y, Halpern S, Carvalho JC: Ultrasound imaging

- of the lumbar spine in the transverse plane: The correlation between estimated and actual depth to the epidural space in obese parturients. *Anesth Analg* 2009; 108:1876-81
45. Bonazzi M, Bianchi De Grazia L, Di Gennaro S, Lensi C, Migliavacca S, Marsicano M, Riva A, Laveneziana D: Ultrasonography-guided identification of the lumbar epidural space. *Minerva Anestesiologica* 1995; 61:201-5
 46. Halpern SH, Banerjee A, Stocche R, Glanc P: The use of ultrasound for lumbar spinous process identification: A pilot study. *Can J Anaesth* 2010; 57:817-22
 47. Karmakar MK, Li X, Ho AM, Kwok WH, Chui PT: Real-time ultrasound-guided paramedian epidural access: Evaluation of a novel in-plane technique. *Br J Anaesth* 2009; 102:845-54
 48. Locks Gde F, Almeida MC, Pereira AA: Use of the ultrasound to determine the level of lumbar puncture in pregnant women. *Rev Bras Anestesiologia* 2010; 60:13-9
 49. Pysyk CL, Persaud D, Bryson GL, Lui A: Ultrasound assessment of the vertebral level of the palpated intercrystal (Tuffier's) line. *Can J Anaesth* 2010; 57:46-9
 50. Schlotterbeck H, Schaeffer R, Dow WA, Touret Y, Bailey S, Diemunsch P: Ultrasonographic control of the puncture level for lumbar neuraxial block in obstetric anaesthesia. *Br J Anaesth* 2008; 100:230-4
 51. Stiffler KA, Jwayyed S, Wilber ST, Robinson A: The use of ultrasound to identify pertinent landmarks for lumbar puncture. *Am J Emerg Med* 2007; 25:331-4
 52. Tran D, Kamani AA, Al-Attas E, Lessoway VA, Massey S, Rohling RN: Single-operator real-time ultrasound-guidance to aim and insert a lumbar epidural needle. *Can J Anaesth* 2010; 57:313-21
 53. Tran D, Kamani AA, Lessoway VA, Peterson C, Hor KW, Rohling RN: Preinsertion paramedian ultrasound guidance for epidural anesthesia. *Anesth Analg* 2009; 109:661-7
 54. Watson MJ, Evans S, Thorp JM: Could ultrasonography be used by an anaesthetist to identify a specified lumbar interspace before spinal anaesthesia? *Br J Anaesth* 2003; 90:509-11
 55. Whitty R, Moore M, Macarthur A: Identification of the lumbar interspinous spaces: Palpation *versus* ultrasound. *Anesth Analg* 2008; 106:538-40
 56. Margarido CB, Arzola C, Balki M, Carvalho JC: Anesthesiologists' learning curves for ultrasound assessment of the lumbar spine. *Can J Anaesth* 2010; 57:120-6
 57. Furness G, Reilly MP, Kuchi S: An evaluation of ultrasound imaging for identification of lumbar intervertebral level. *Anaesthesia* 2002; 57:277-80
 58. Chin KJ, Chan VW, Ramlogan R, Perlas A: Real-time ultrasound-guided spinal anesthesia in patients with a challenging spinal anatomy: Two case reports. *Acta Anaesthesiologica Scandinavica* 2010; 54:252-5
 59. Chin KJ, Macfarlane AJ, Chan V, Brull R: The use of ultrasound to facilitate spinal anesthesia in a patient with previous lumbar laminectomy and fusion: A case report. *J Clin Ultrasound* 2009; 37:482-5
 60. Costello JF, Balki M: Cesarean delivery under ultrasound-guided spinal anesthesia in a parturient with poliomyelitis and Harrington instrumentation. *Can J Anaesth* 2008; 55:606-11
 61. Minville V, Lavidalle M, Bayoumeu F, Parrant O, Fourcade O: Ultrasound-assisted spinal anesthesia in obstetric patient with corrected scoliosis. *Ann Fr Anesth Reanim* 2010; 29:501-2
 62. O'Donnell D, Prasad A, Perlas A: Ultrasound-assisted spinal anesthesia in obese patients. *Can J Anaesth* 2009; 56:982-3
 63. Pandin P, Haentjens L, Salengros JC, Quintin J, Barvais L: Combined ultrasound and nerve stimulation-guided thoracic epidural catheter placement for analgesia following anterior spine fusion in scoliosis. *Pain Pract* 2009; 9:230-4
 64. Prasad GA, Simon G, Wijayatilake S: Ultrasound-assisted epidural blood patching. *Int J Obstet Anesth* 2008; 17:376-7
 65. Prasad GA, Tumber PS, Lupu CM: Ultrasound guided spinal anesthesia. *Can J Anaesth* 2008; 55:716-7
 66. Somers R, Jacquemyn Y, Sermeus L, Vercauteren M: Corrected scoliosis, cholinesterase deficiency, and cesarean section: A case report. *Case Report Med* 2009; 2009:957479
 67. Whitty RJ, Maxwell CV, Carvalho JC: Complications of neuraxial anesthesia in an extreme morbidly obese patient for Cesarean section. *Int J Obstet Anesth* 2007; 16:139-44
 68. Yeo ST, French R: Combined spinal-epidural in the obstetric patient with Harrington rods assisted by ultrasonography. *Br J Anaesth* 1999; 83:670-2
 69. Bellingham GA, Peng PW: A low-cost ultrasound phantom of the lumbosacral spine. *Reg Anesth Pain Med* 2010; 35:290-3
 70. Kwok WH, Chui PT, Karmakar MK: Pig carcass spine phantom: A model to learn ultrasound-guided neuraxial interventions. *Reg Anesth Pain Med* 2010; 35:472-3
 71. de Filho GR, Gomes HP, da Fonseca MH, Hoffman JC, Pederneiras SG, Garcia JH: Predictors of successful neuraxial block: A prospective study. *Eur J Anaesthesiology* 2002; 19:447-51
 72. Auroy Y, Narchi P, Messiah A, Litt L, Rouvier B, Samii K: Serious complications related to regional anesthesia: Results of a prospective survey in France. *ANESTHESIOLOGY* 1997; 87:479-86
 73. Harrison DA, Langham BT: Spinal anaesthesia for urological surgery. A survey of failure rate, postdural puncture headache and patient satisfaction. *Anaesthesia* 1992; 47:902-3
 74. Horlocker TT, McGregor DG, Matsushige DK, Schroeder DR, Besse JA: A retrospective review of 4767 consecutive spinal anesthetics: Central nervous system complications. Perioperative Outcomes Group. *Anesth Analg* 1997; 84:578-84
 75. Kawaguchi R, Yamauchi M, Sugino S, Tsukigase N, Omote K, Namiki A: Two cases of epidural anesthesia using ultrasound imaging. *Masui* 2007; 56:702-5
 76. Chin KJ, Perlas A, Chan V, Brown-Shreves D, Koshkin A, Vaishnav V: Ultrasound imaging facilitates spinal anesthesia in adults with difficult surface anatomical landmarks. *ANESTHESIOLOGY* (in press)
 77. Hamandi K, Mottershead J, Lewis T, Ormerod IC, Ferguson IT: Irreversible damage to the spinal cord following spinal anesthesia. *Neurology* 2002; 59:624-6
 78. Reynolds F: Damage to the conus medullaris following spinal anesthesia. *Anaesthesia* 2001; 56:238-47
 79. Willschke H, Bosenberg A, Marhofer P, Willschke J, Schwindt J, Weintraud M, Kapral S, Kettner S: Epidural catheter placement in neonates: Sonoanatomy and feasibility of ultrasonographic guidance in term and preterm neonates. *Reg Anesth Pain Med* 2007; 32:34-40
 80. Dick EA, Patel K, Owens CM, De Bruyn R: Spinal ultrasound in infants. *Br J Radiol* 2002; 75:384-92
 81. Bron JL, van Royen BJ, Wuisman PI: The clinical significance of lumbosacral transitional anomalies. *Acta Orthop Belg* 2007; 73:687-95
 82. Tyl RW, Chernoff N, Rogers JM: Altered axial skeletal development. *Birth Defects Res B Dev Reprod Toxicol* 2007; 80:451-72
 83. Kim JT, Bahk JH, Sung J: Influence of age and sex on the position of the conus medullaris and Tuffier's line in adults. *ANESTHESIOLOGY* 2003; 99:1359-63
 84. Saranteas T: Limitations in ultrasound imaging techniques in anesthesia: Obesity and muscle atrophy? *Anesth Analg* 2009; 109:993-4